

# EFSUMB Course Book, 2nd Edition

**Editor: Christoph F. Dietrich**

## **Ultrasound of the kidneys and ureter**

**J. Tuma<sup>1</sup>, F. Trinkler<sup>2</sup>, F. Zátura<sup>3</sup>, B. Nováková<sup>4</sup>, A. Serra<sup>1</sup>**

<sup>1</sup>Ultrasound Learning Center, Hirslanden Clinic.

<sup>2</sup>Urozentrum Zürich.

<sup>3</sup>Urologic Clinic FN Olomouc.

<sup>4</sup>Clinic of Gastroenterology Košice.

**Corresponding author:**

Associate Prof. Jan Tuma,

Co-Director EFSUMB Ultrasound Learning Center, Hirslanden Clinic

Witellikerstrasse 40, 8032 Zürich, Switzerland.

Tel. +41 044 387 20 66 Email: [Jan.Tuma@hirslanden.ch](mailto:Jan.Tuma@hirslanden.ch)

**Acknowledgment:**

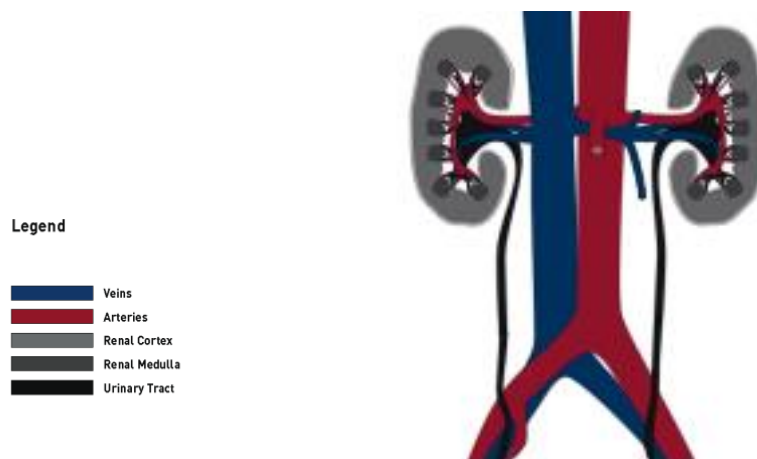
The authors thank Tomas Brader for all Illustrations in this chapter and Anthony Rudd for copy editing.

# Kidney

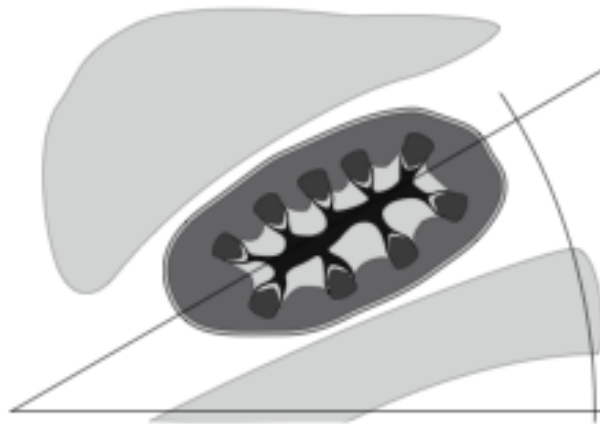
## Topography

The urogenital system is located retroperitoneally. The kidneys are situated next to liver and spleen, close to psoas muscle and the large abdominal vessels. Dorsal to the kidney lies the iliopsoas muscle, ventrally is either the liver or spleen, medially and ventrally are the large abdominal vessels. The longitudinal axis points from cranial-medial to caudal-lateral and from cranial-dorsal to caudal-ventral. This is important for the accurate measurement of renal length. In its short axis, the renal hilum points in a ventral medial direction [Figure 1–4].

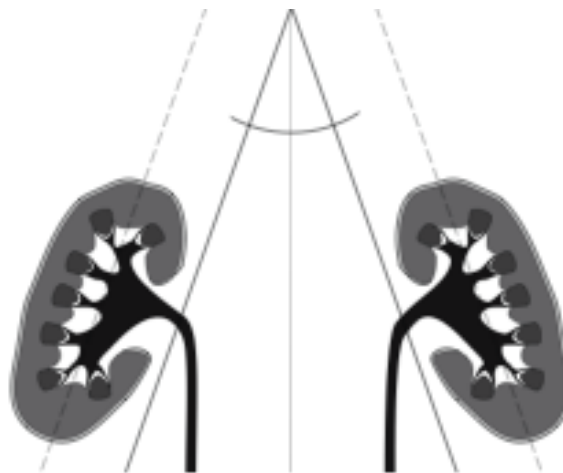
**Figure 1** Normal position of kidneys and ureters.



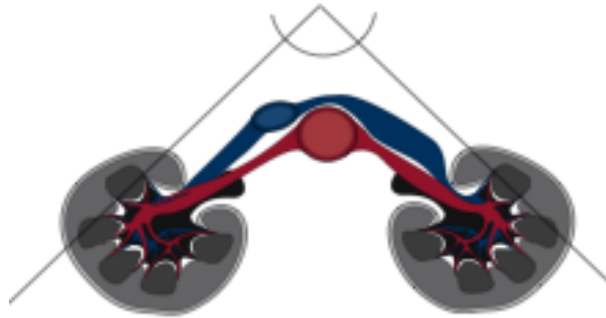
**Figure 2** In the sagittal plane, the longitudinal axis points in a dorsal cranial to ventral caudal direction.



**Figure 3** In the frontal plane, the longitudinal axis points in a medial cranial to lateral caudal direction.



**Figure 4** The short axis points in a dorsal lateral to ventral medial direction.



## Anatomy

The macroscopic structure of the kidney is well depicted on sonography. In obese patients, the outer kidney capsule limits the perirenal fat body and the inner kidney echogenic capsule represents a kidney contour. The parenchyma can be differentiated in the echogenic renal cortex as well as the 12–15 echo poor pyramids that point conically towards the limit of the kidney sinus. Between the pyramids, the kidney cortex reaches up to the sinus. The bases of the pyramids are limited by the light reflex of the arcuate artery. In the longitudinal axis, the more echogenic and inhomogenous oval kidney sinus can be seen in the middle of the parenchyma; in cross-section it appears semi-circular [Figure 5 and 6].

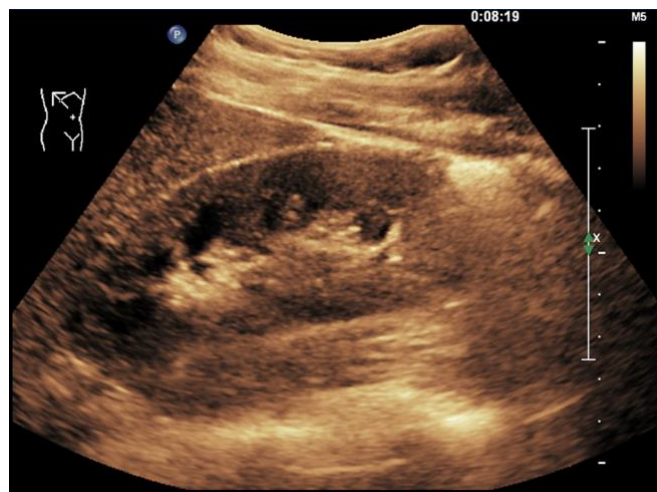The renal artery and vein are observed emerging at a right angle from the renal hilum. The right kidney vein merges directly into the vena cava, whereas the left vein first crosses the aorta ventrally. The right renal artery points behind the vena cava to the renal hilum [Figure 1 and 7].

The ureters emerge from the renal hilum caudally. They then proceed along the psoas muscle and cross the iliac vessels to reach the ureteral orifices of the bladder retroperitoneally [Figure 1]. This anatomical course is important when looking for ureteric stones.

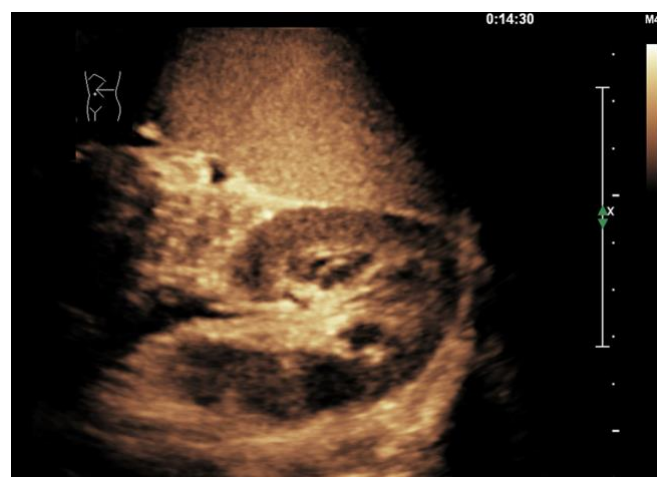The urinary collecting system is easily recognised when there is urinary obstruction. With the patient lying in the prone position, the renal pelvis should be easily visible in most cases. The exit of the ureter can be seen in this position [Figure 8].

The basic functional unit of the kidney is the renal lobule [Figure 9 and 10], which consists of a renal pyramid with the surrounding kidney cortex and is a similar size to a rats kidney, which has one lobule only. In the human kidney between 12 and 15 lobules merge together. Occasionally evidence of this merging (or lobulation) can be seen [Figure 11], especially during childhood, and this is a normal variation [Figure 12].

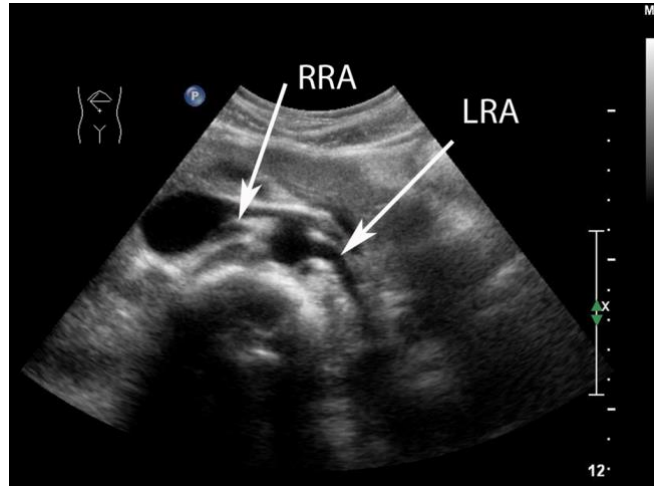
**Figure 5** Longitudinal view: right kidney lies behind the liver and lies on m.psoas.



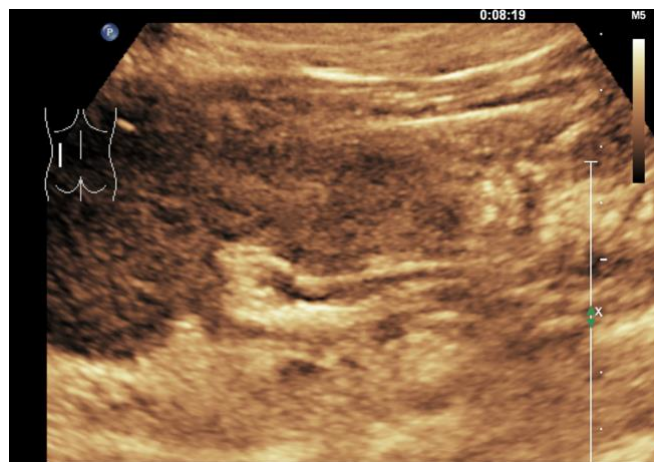**Figure 6** Cross-section view: left kidney behind spleen.



**Figure 7** Renal vessels. RRA, right renal artery; LRA, left renal artery.



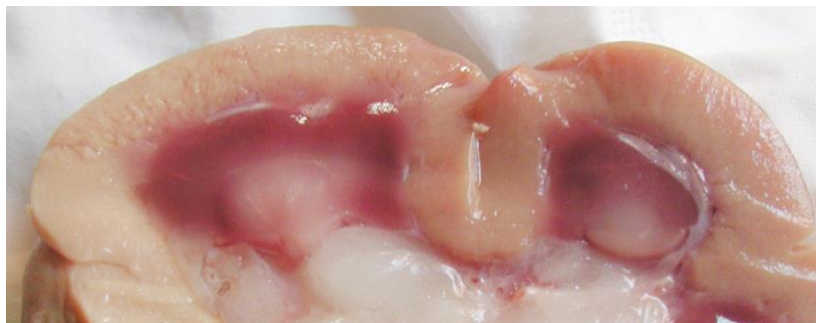
**Figure 8** Ureter outlet in prone position clearly visible as tubular structure.



**Figure 9** A renal lobule includes a single pyramid surrounded by the cortex.



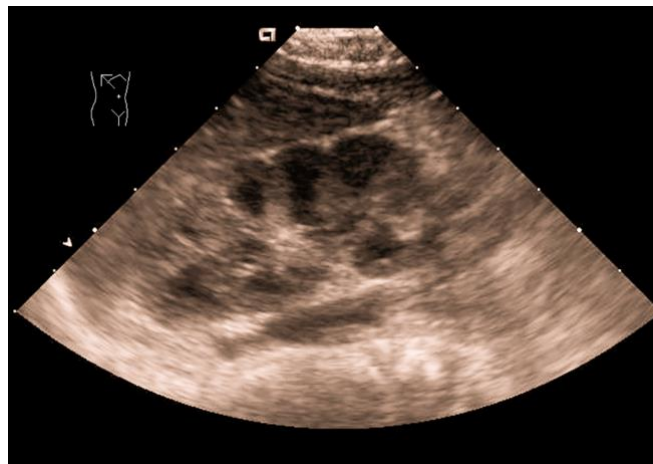
**Figure 10** Two adjacent lobules of a calf kidney. The lighter kidney cortex and darker pyramids are clearly visible.



**Figure 11** Lobulation, areas of renal lobule fusion are easily recognisable, especially in children.



**Figure 12** Foetal lobulation in an 8-year-old child.



### Normal findings

#### *Size*

The normal kidney measurements ([1]) are as follows:

Length (A): 9–13cm (measured in longitudinal section)



Width (B): 4–6cm (measured in cross-section)

Depth (C): 4–6cm (measured in cross-section)

Using the ellipsoid formula, the kidney volume is calculated by:

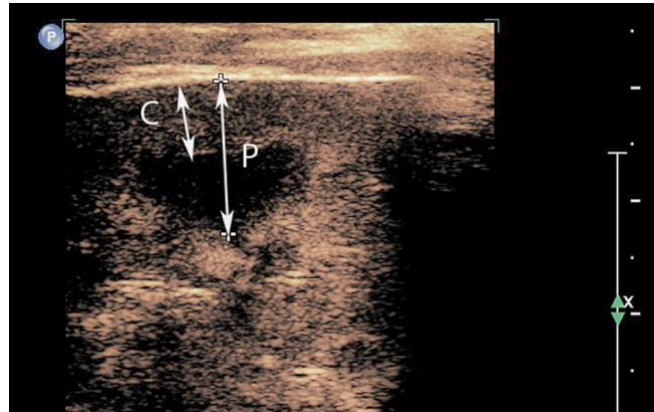
Volume in millilitres =  $A \times B \times C \times (\pi/6)$

Normal kidney volume is 90–170ml/1.73m<sup>2</sup>. Correct measurement of the kidney volume should involve both the longitudinal- and cross-axis of the kidney [(1,2)]. Kidneys with a volume greater than 200ml/1.73m<sup>2</sup> BSA are enlarged and kidneys with a volume under 80ml/1.73m<sup>2</sup> BSA are shrunken [(1, 2)].

### ***Parenchymal and cortical thickness***

The parenchymal thickness is measured from the tip of the renal pyramid to the surface of the kidney [(2)]. Normal parenchymal thickness is 14–18mm. Parenchymal thickness can be useful but the measurement should always be carried out in the same place, *i.e.* at the same pyramids [Figure 13]. This is particularly important while monitoring a transplanted kidney, but should also be taken into account when assessing chronically diffuse diseases of the parenchyma. The cortical thickness is measured from the tip of renal pyramid to the kidney cortex surface [Figure 13]. The normal cortical thickness is 8–10mm. The cortex narrows in chronic diseases of the parenchyma and is associated with kidney insufficiency. As a result cortical thickness correlates with the degree of the kidney insufficiency [(3, 4)].

**Figure 13** Measurement of parenchymal (P) and cortical (C) thickness.



The vascular supply of the kidneys is divided into five segments the upper pole, lower pole, upper anterior, lower anterior and posterior segment. In only 60% of the population will all 5 segments originate from a single renal artery. In 8% the upper pole artery originates directly from the aorta, in 6% the lower pole artery and in 5% both pole arteries. Segment arteries divide themselves shortly before entering the kidney parenchyma. First, they give rise to the interlobar arteries then branch into the arch arteries. Further divisions of the arch arteries consist of the vasa recta leading into the renal medulla and the interlobular arteries leading into the kidney cortex.

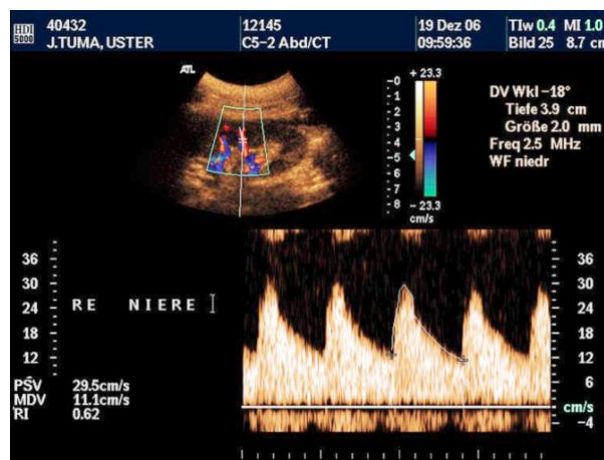
### Examination technique

The patient is first examined supine. The longitudinal axis is looked for along the edge-cut, a section which runs in a dorsal-cranial to ventral-caudal direction and in a medial cranial to caudal lateral direction. The kidney is first measured in the longitudinal plane and then in the short-axis and cross-section. The ribs can sometimes obstruct a clean cross-section. If this occurs, it is recommended the examiner finds a space between the ribs and asks the patient to breathe deeply. The whole kidney can then be examined properly and in detail. The kidney sinus is usually easily examined when the patient (either child or adult) is in the prone position. This position is usually successful for the identification of the renal pelvis and the outlet of the ureter. The kidneys can be positioned quite high and the left kidney can be subphrenic. In these cases, examination in a standing position is usually successful. This can lead to the

observation of a floating kidney (the kidney moves >5cm while standing). It is important to observe the respiratory displacement of the kidney and to compare it with the respiratory displacement of the liver (and the spleen on the left side) and the psoas muscle. Single focal space demands can then be distinguished from each other, *e.g.* cysts in kidney or spleen. A lack of displacement in comparison with the psoas muscle suggests a perinephric abscess or infiltration of the kidney by a retroperitoneal tumour.

To assess renal perfusion, a spectral analysis of the kidney parenchymal artery is obtained while the patient lies in prone [Figure 14]. Spectral curves are evaluated from arteries at the point where they are about to dip into the kidney parenchyma. Renal arteries and veins are assessed with the patient in supine position. Outlets of the renal arteries can be observed in the longitudinal axis [Figure 15–16] as well as in cross-section [Figure 8]. In cross-section, the entire length of the arteries can be seen on colour duplex ultrasonography (CDUS). Spectral analysis can be derived from a cross-section as well as in the longitudinal axis.

**Figure 14** Spectral curves from interlobar artery (representing renal parenchyma).



**PREVIEW CHAPTER ONLY** FOR THE REMAINING 89 PAGES PLEASE PURCHASE THE FULL CHAPTER. You can purchase the full chapter for just 2.99 GBP by clicking on the link below and completing your purchase on the Secure PayPal server.

 **PayPal** Check out

The safer, easier way to pay