EFSUMB Course Book, 2nd Edition

Editor: Christoph F. Dietrich

CLASSIFICATION AND US MANAGEMENT OF MUSCLE INJURIES IN SPORT

Fernando Jimenez Díaz[1], Nirvikar Dahiya[2], Christian Kollmann[3]

[1]Professor in Sport Sciences Faculty. Castilla la Mancha University. Director of MSK US International Chair, UCAM. Spain. [2]Associate Professor, Chair Ultrasound Division, Department of Radiology. Mayo Clinic, Phoenix, Arizona, USA. [3]Assist. Prof. Dr. techn. Center for Medical Physics & Biomedical Engineering. Medical University of Vienna. Austria.

Corresponding author:

Fernando Jiménez Díaz MD, PhD, Sport Sciences Faculty. Castilla la Mancha University. Campus Tecnólogico Antigua Fábrica de Armas. Avd. Carlos II, s/n. Toledo 45071. Spain. Josefernando.jimenez@uclm.es

Acknowledgement: The authors thank Professor A. Rudd for advice.

Introduction

Muscle injuries are very frequent in sports [(1, 2)], with an incidence that varies between 10% and 55% of all injuries [(3, 4)]. The mechanisms of injury are varied and include bruising, stretching or laceration. Muscle lacerations are the least frequent injuries, while bruises and strains occur in 90% of all cases of muscle involvement [(5)].

Little information is available in the international literature about muscle injury definitions and classification systems. The establishment of a classification of sports injuries has always been an important topic for discussion. Additionally, muscle injuries have been difficult to define and classify because the muscles have different sizes and shapes with a complex functional and anatomical organisation [(6)].

The evaluation of muscle injury should begin with a complete medical history followed by a detailed physical examination including palpation, which allows one to detect the size of the muscle defect [(5, 7, 8)]. The ultrasound should be performed between 2 and 48 h after the muscle trauma [(9)], although it is acceptable to wait for a period of 48 - 72 h. This interval allows for the injury to get organised and the tissue show changes easily detected by ultrasound.

The choice of the transducer depends on the size and depth of the muscle to be examined. It is common to use multi-frequency probes between 7-12 MHz, for most cases. In very obese patients, those with hypertrophy of the musculature or in the study of deep muscles (piriformis), it may be necessary to use lower frequency transducers. In this chapter all the images have been made on the short and long axis of each muscle, using an 8 – 12 MHz multifrequency transducer.

MRI is also useful to confirm the location of the lesion and any compromise of the tendon [(7)], although not sensitively enough to accurately measure the extent of muscle tissue damage.

Old models of classification of muscle injury

These are the reasons why several classifications have been published in recent years, some supported by clinical signs such as the one published by O´Donoghue [(10)] that related the

severity of the injury with the amount of tissue damage and the associated functional loss, establishing three grades. Grade 1 without appreciable tissue tearing, grade 2 with tissue damage and reduced strength of the musculotendinous unit and grade 3 with complete tearing of the musculotendinous unit and complete loss of function [(10)].

Another author, Ryan, applied the classification for the study of quadriceps lesions by dividing them into 4 degrees [(11)].

Takebayashi et al [(12)] published for the first time a classification supported by ultrasound. Grade 1 lesions with less than 5% of the muscle involved, grade 2 for a partial rupture with more than 5% of the muscle involved and up to grade 3 with a full tear. Peetrons in 2002 recommended a classification also supported by ultrasound [(9)].

However, the most commonly used classification is an MRI-based gradation system and establishes four grades: grade 0 without pathological findings, grade 1 with muscle oedema alone but without tissue damage, grade 2 a partial muscle tear and grade 3 with a complete muscle tear [(13)].

However, the classification of lesions that best suits the use of ultrasound as a diagnostic tool is that published in the Munich Consensus Statement [(14)]. Therefore, we recommend following this model in the management of muscle injuries in sport.

In the sports environment the first group of injuries are those caused by an extrinsic mechanism or direct shock, which includes muscle bruises, which are more frequent in occupational accidents and sports activities, especially in contact sports and in collective sports. The second group is made up of those injuries secondary to intrinsic trauma, as a result of violent movements and exaggerated contractions, which cause a sudden tension in the muscle groups, causing the breakage of their fibres. This lesion is very frequently observed in jumpers and sprinters, with hamstring muscles, the rectus femoris and the medial gastrocnemius being more frequently affected.

Classification of muscle injury based on ultrasound exam

In 2012, the Munich Muscle Injury Classification was developed by 15 international sports injury experts based on their combined experience with over 400 thigh injuries in professional athletes, dividing the injuries into 8 categories [(14)]. This system separates muscle injuries into three categories: functional disorders, strain, and contusion.

The Consensus Munich Statement is our usual classification model because, unlike other classifications, it adapts perfectly to ultrasound examinations. Within this consensus, injuries caused by an Indirect muscle disorder and those caused by Direct muscle injury are distinguished. The first group includes the functional muscle disorder and the structural muscle injury. We will describe the ultrasound characteristics of this muscle lesions following this consensus statement.

Direct muscle injury

Contusion is an acute injury caused by a direct nonpenetrating blow to the muscle, typically affecting the anterior thigh, posterior thigh, or anterolateral upper arm [(15)]. When the impact occurs on a muscle that is in the contraction phase, the lesion affects the most superficial fibres, while, if the impact is received in the relaxation phase, the lesion reaches the deep fibres that are located near the bone.

Considering the clinical and ultrasound signs, these lesions can be classified into three grades. Mild or first-degree bruises cause little capillary rupture with a small amount of bleeding that causes a small area of ecchymosis in the skin. Flexion pain only appears with full flexion and ultrasound shows small hyperechoic areas in the subcutaneous cellular tissue and muscle tissue due to the presence of an inflammatory changes that invade the interstitial space [Figure 1]. In second degree contusions, fibrillar crushing causes a bruise that produces a functional limitation, allowing flexion above 90 degrees. Ultrasound will show one or several cavities of anechoic content and irregular borders, sometimes occupied by hypoechoic areas [Figure 2]. Finally, in grade three contusions, the amplitude of the fibrillar and vascular damage is greater, which causes a limitation of flexion below 90 degrees and the ultrasound image shows large anechoic haematomas caused by the crushing of muscle fibres [Figure 3].

Figure 1 **First degree extrinsic muscle injury. The longitudinal image of the gastrocnemius medialis, shows the muscle with irregular borders and hyperechoic appearance, that corresponds to the contusion. The soleus muscle is also affected.**

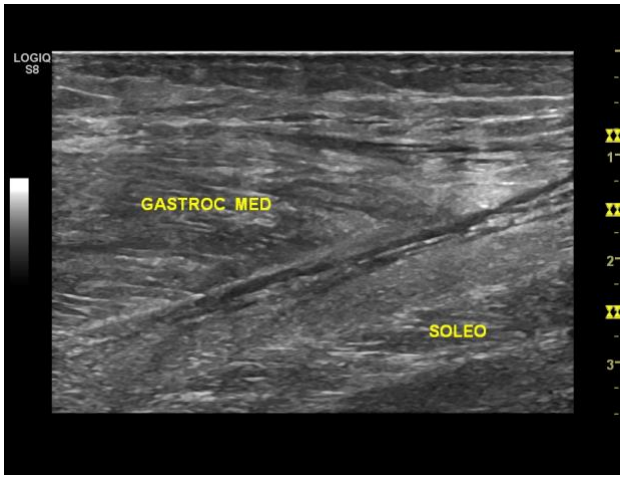

Figure 2 **Second degree extrinsic muscle injury. The longitudinal image of the vastus lateralis and rectus femoris muscles shows an anechoic area that infiltrates both muscles.**

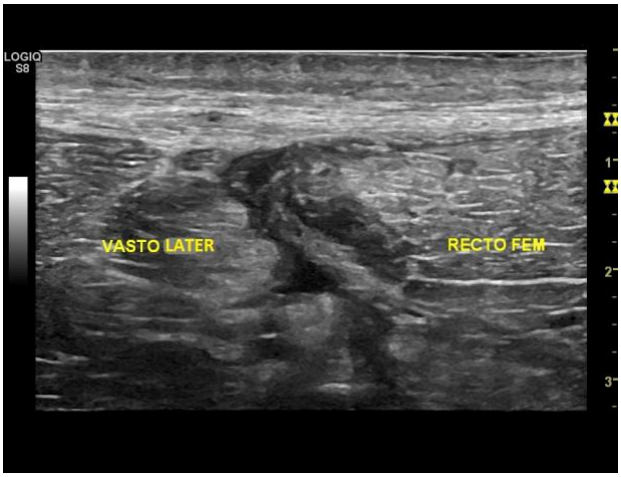

Figure 3 **Third degree extrinsic muscle injury. The US examination of the lateral aspect of the thigh shows an anechoic defect that divides into two compartments (0.88 and 1.28 cm thick), corresponding to the haematoma produced by blunt trauma.**

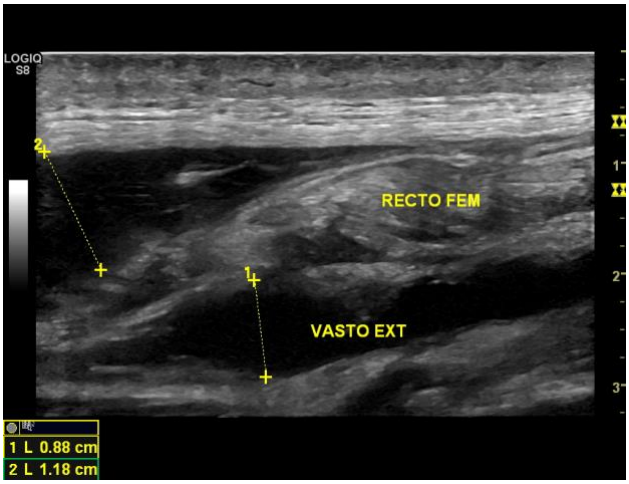

Finally, in some bruises, the subcutaneous cellular tissue is affected with thickening taking on an hyperechoic appearance, sometimes accompanied by serous effusions trapped between the subcutaneous fat and the deep fascia also known as Morel-Lavallee effusion [Figure 4].

Figure 4 **Morel Lavallee serous effusion. In this patient, an anechoic area with regular borders is visualised, which is located below the subcutaneous plane (SP), without affecting the vastus lateralis muscle (VL). This image corresponds to a serous effusion of Morel Lavallee, as a result of a bruise on the leg.**

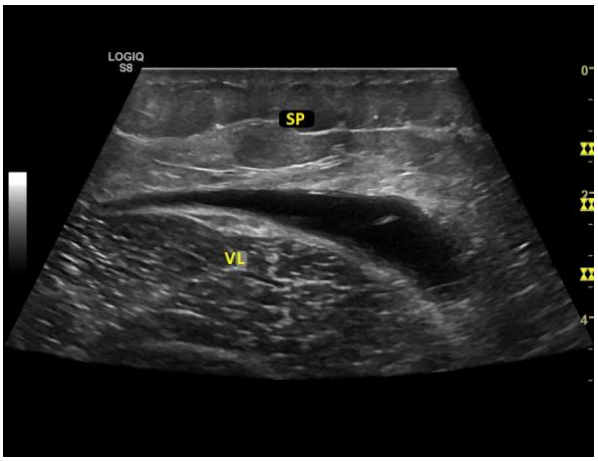

Indirect muscle disorder or injury

Strain is an acute indirect muscle injury that occurs during activity, typically related to excessive stretching of a contracted muscle during eccentric exercise while engaged in sports that emphasize speed and power, such as soccer, American football, rugby, and track and field [(16)]. In these situations, the elasticity of the muscle can be overcome, during an eccentric muscular activation.

The risk of injuries due to muscular distraction increases in high-demand sports and represents a high percentage of all acute sports injuries. The most commonly injured muscles are the hamstrings, the rectus femoris and the medial head of the gastrocnemius, all with a higher percentage of type II fibres, a bipennate architecture, which cross two joints and are usually injured during the eccentric phase of muscle contraction. Although the diagnosis is usually clinical, imaging allows to assessment of its extent and location, as well as the relevant prognostic factors in terms of recovery time, return to play after the injury and the risk of recurrence.

Through a classification based on the time of evolution, two types of indirect muscle disorder or injury are distinguished [(14)]. Functional muscle disorder that include overexertion-related, muscle disorder and neuromuscular muscle disorder (less frequent), and on the other hand, the structural muscle injury, including muscle tears.