Professor Luigi Bolondi, Honorary Member of EFSUMB

Christoph F Dietrich[1], Yi Dong[2]

[1]Kliniken Hirslanden Beau-Site, Salem und Permanence, Bern, Switzerland; Johann Wolfgang Goethe University Frankfurt, Germany; EFSUMB President (2013-2015)

[2]Department of Ultrasound, Zhongshan Hospital, Fudan University, Shanghai, China

Corresponding Author

Christoph F. Dietrich, MD, PhD, MBA, Professor

Chefarzt DAIM, Department Allgemeine Innere Medizin

Kliniken Hirslanden Beau Site, Salem und Permanence

Schänzlistrase 39

CH-3013 Bern

Tel: 41 (0)76 4408150

Christophfrank.dietrich@hirlsanden.ch

Explanation

The following chapter has been published in the *Festschrift* "Luigi Bolondi Felicitations Volume-Studies in Medicine and its history" C Borghi, P Ognibene, A Panaino Eds. Mimesis Publ 2021.

Summary

Herewith and as part of celebrating the edition of a Felicitations Volume in honour of our esteemed colleague and friend Professor Luigi Bolondi, who has retired after a long and seminal career, we present an individually choosen summary of his worldwide recognized published papers as a sign of collaboration and friendship.

Acknowledgement

We kindly acknowledge reading and advice from Lynne Rudd, esteemed EFSUMB and WFUMB Secretary and Annalisa Berzigotti for review.

The first publications

In 1976, Prof. Luigi Bolondi focused very early as a pioneer in ultrasound of pancreatic disease. He first published a paper in Gut [(1)]. The authors have proven that there was good agreement between the echographic picture and surgical findings of pancreatic diseases. It concluded that echography is a simple, safe, and valuable method in addition to the imaging techniques available for studying the pancreas [Figure 1]

Figure 1 Pseudocyst of the tail of the pancreas (arrow) in chronic calcifying pancreatitis.

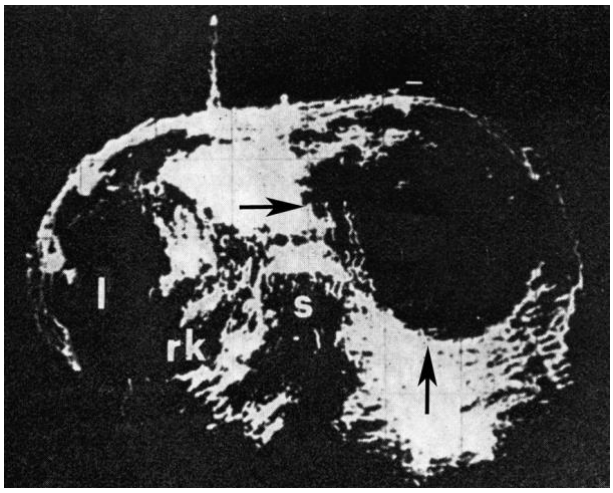

In 1978, Prof. Luigi Bolondi pioneered the study of the portal venous system and portal hypertension using ultrasonography. In his Lancet publication [(2)] he showed that, on the oblique scans, the right portal vein is always clearly recongnisable near the porta hepatis [Figure 2], and Ultrasound (US) can therefore be considered a simple, safe, rapid and important technique in the diagnosis of extrahepatic portal venous obstruction.

Figure 2 The portal vein (PV) on oblique section of abdominal ultrasound.

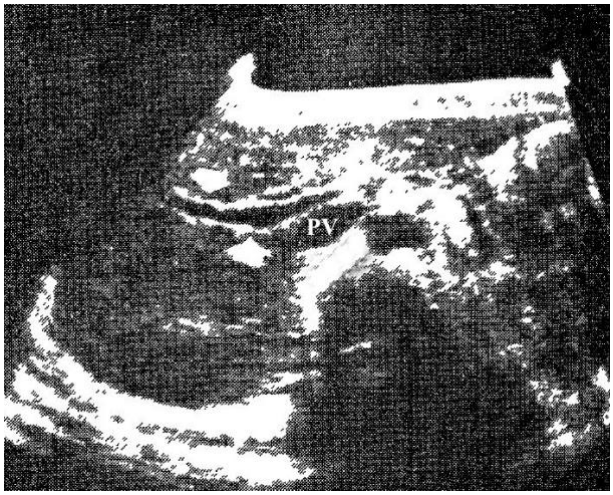

After addressing the pancreas and the portal venous system, in 1979, Prof. Bolondi published a paper in the American Journal of Gastroenterology [(3)] on the use of US as a first step in the diagnostic approach to cholestasis. Since then, information gained from this noninvasive technique makes it possible to correctly plan the more complex investigations such as endoscopic retrograde cholangiopancreatography (ERCP) and percutaneous transhepatic cholangiography (PTCD) [Figure 3].

Figure 3 Cholecystolithiasis (arrow) could be visualized inside of the gallbladder (GB) on oblique section of gray scale ultrasound.

Masterpieces

Gastroenterology

In 1985, Prof. Bolondi published a paper in Gastroenterology, which described a new ultrasound method of assessing gastric emptying time based on measurements of the gastric antrum, which is visible in almost all subjects before and after meals. They concluded that this kind of ultrasound study of the antropyloric region allowed accurate determination of total gastric emptying time [(4, 5)].

In 1986, Prof. Bolondi evaluated by ultrasound the number and anatomical correspondence of the sonographically recognizable layers within the gastric wall in vivo. For the first time in ultrasound history, they took into account the physical laws of ultrasound interactions with tissues and concluded that the 1st and the 5th hyperechoic layers were partially generated by ultrasound reflection at the interface liquid/wall; the 2nd hypoechoic layer corresponded to the deepest part of the mucosa; the 3rd hyperechoic to the submucosa and the submucosa/muscularis propria interface and the 4th hypoechoic layer to the muscularis propria. These findings opened a new era for the clinical ultrasound applications in the diagnosis of gastric wall diseases [(6-9)] [Figure 4 and 5]. He also undertook pioneering research on the ultrasound application in ulcerated Meckel's diverticulum [(10)] and the pseudomembranous colitis [(11)].

Figure 4 **Normal appearance of five layers within the stomach wall (arrows), which could be well visualized by endoscopic ultrasound *in vivo* after water filling of the stomach.**

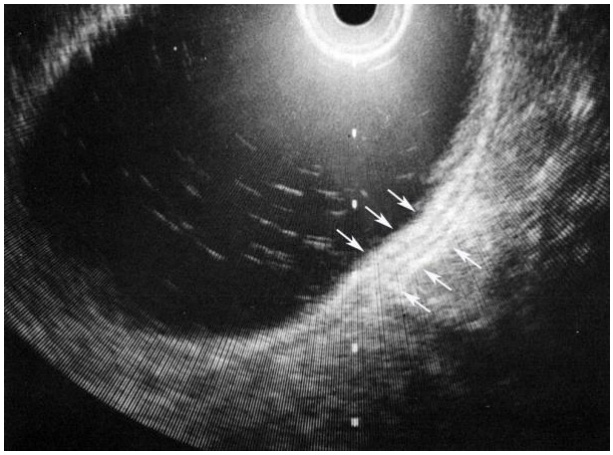

Figure 5 **Normal appearance of five layers within the stomach wall (arrow) could be well recognized by conventional transabdominal ultrasound.**

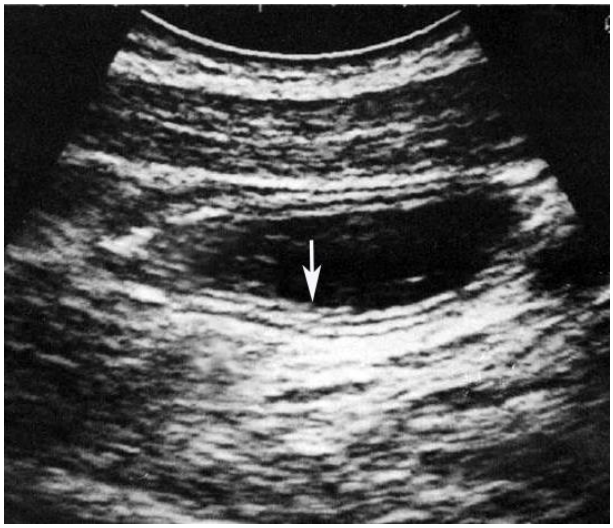

Endoscopic ultrasound (EUS) enables high-resolution imaging of the stomach and can demonstrate the different layers of the gastric wall. Therefore, EUS was proposed by Prof. Bolondi in 1987 for the use in evaluating the extension of gastric neoplasms. Three different ultrasound patterns were found in gastric lymphomas [Figure 6]. However, gastric

carcinomas had a more echogenic pattern and a different trend of diffusion, with no extended longitudinal hypoechoic infiltration of the superficial layers or extended hypoechoic transmural infiltration [(12)]. Ever since then, endoscopic ultrasound became more and more useful in detecting the early stages of infiltration of gastric malignant tumours [(13, 14)] when the overlying mucosa was still intact [(15)] [Figure 7].

Figure 6 **Diffuse gastric lymphoma with extended longitudinal thickening (arrows) of the gastric wall (2 cm thick) and complete disappearance of normal layers [(12)].**

Figure 7 **Endoscopic sonogram showed an infiltrating carcinoma at the level of the antrum. Layers in the infiltrated wall (arrows) were not recognizable, and the structure showed alternating hypo- and hyperechoic areas [(12)].**

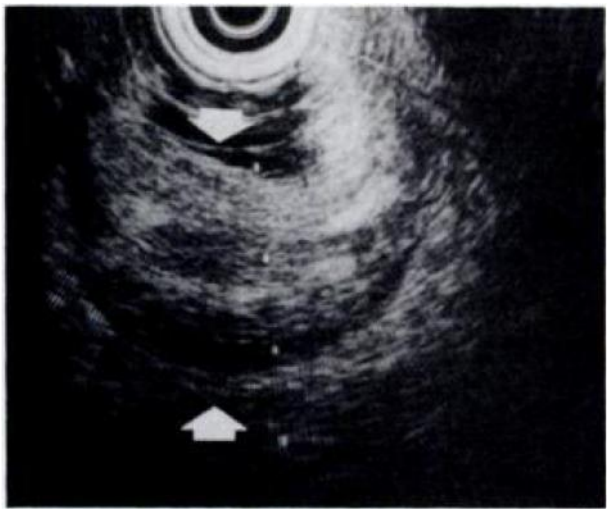

Endoscopic ultrasound also contributed to a correct diagnosis in gastric submucosal tumours. Leiomyoma and lipoma were easily recognized by their location and echogenicity [Figure 8]. In gastric submucosal tumours, endosopic ultrasound can reduce the need for aggressive and risky biopsy or exploratory laparotomy [(14)].

Figure 8 A leiomyoma (arrow) mimicking a large polypoid lesion was detected within the water-filled stomach.

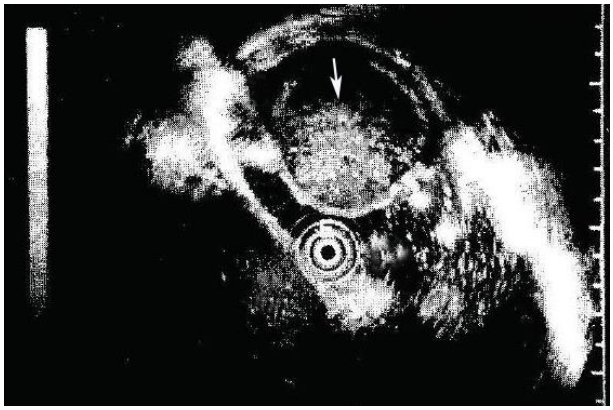

Portal Hypertension (with and without Budd Chiari Syndrome, BCS)

The first application of ultrasound in the assessment of the portal venous system was reported in the Lancet in the year 1978 [(2)]. In 1982, Prof. Bolondi assessed the usefulness

of ultrasound in the diagnosis of portal hypertension due to liver cirrhosis [Figure 9]. For the first time, a lack of normal caliber variation (an increase during inspiration and a decrease during expiration) in the vessels of the portal venous system was proposed as an ultrasound sign of portal hypertension. The pathophysiological and clinical significance of these findings are discussed in detail [(16-18)]. The sonographic findings in portal hypertension and its correlation with the presence and size of oesophageal varices were also evaluated and reported [(19-22)].

Figure 9 Portal hypertension due to liver cirrhosis. Patent and dilated umbilical vein both in transverse (a) and sagittal scan (b) [(16)].

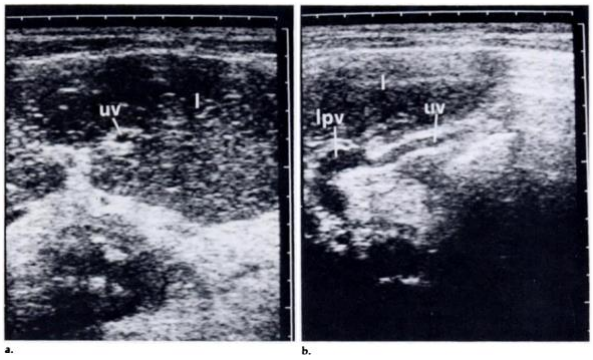

In 1991, Prof. Bolondi showed that Doppler ultrasonography provided qualitative data on flow direction and pattern in the hepatic venous system, thereby contributing significantly to the diagnosis of Budd-Chiari syndrome (BCS) [(23-26)]. Their findings demonstrated that absent or reversed flow in the hepatic veins and/or flat flow in the hepatic veins are associated with reversed flow in the inferior vena cava and may be considered diagnostic for BCS [(24)]. They further assessed the interobserver, interequipment, and time-dependent variabilities of echo-Doppler measurements of portal blood flow velocity (PBV), portal vein diameters (PVDs) and their derived parameters, portal blood flow (PBF), and congestion index (CI) in patients with cirrhosis [Figure 10]. Their results were published in Hepatology and indicated that (1) a significant systematic variability exists between Doppler measurements with different equipment; (2) there is no significant time-dependent systematic variability of Doppler measurements; and (3) a cooperative training program reduces the interobserver variability for direct measurements, such as PBV [(27-29)].

Figure 10 Changes in subdivision of variance components after cooperative training.

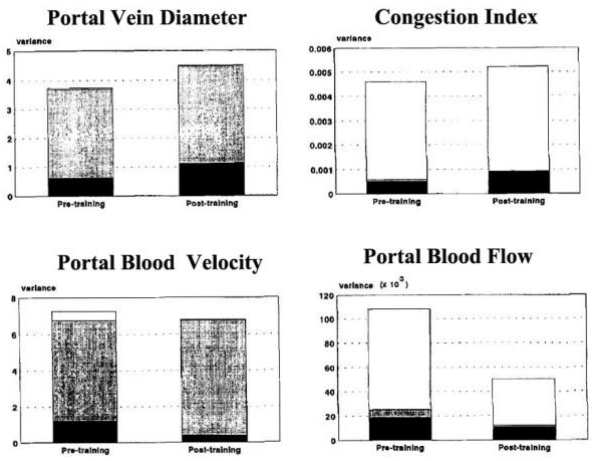

Since the 1980s, a quantitative measurement of the volume of blood flow by Doppler flowmetry was attempted in some of the major abdominal arteries and veins, but the reliability of these measurements was still questioned [(30, 31)]. Systematic variability existed among mesenteric Doppler measurements obtained by different operators using different commercially available equipment [(32-34)]. Prof. Bolondi suggested that the qualitative information on flow pattern provided by Doppler investigation not only contributed to clarifying doubtful images in real-time ultrasound, but also provide new insights into many clinical conditions [(35, 36)].

Prof. Luigi Bolondi and his team first reported the sonographic visualization of the distal end of the thoracic duct [Figure 11]. Its diameter is small in healthy young subjects, whereas in patients with cirrhosis its increased diameter seems to be associated only with the presence of portal hypertension and not with its severity [(20, 37)].

In another study they evaluated the effect of two different doses of secretin on portal haemodynamics (by pulsed Doppler associated with real time ultrasound) in 24 healthy humans. They suggested that secretin had an appreciable vasoactive effect and induced a significant increase in portal venous flow even at doses much lower than those necessary for a maximal stimulation of exocrine pancreatic secretion [(38)].

Figure 11 Transverse sonograms of left supraclavicular are of healthy subject (A) and a patient with cirrhosis and portal hypertension (B). Color Doppler sonography was used to identify the distal end of the thoracic duct (TD) as vessel like structure draining into the internal jugular vein (IJV) and without detectable blood flow within it.

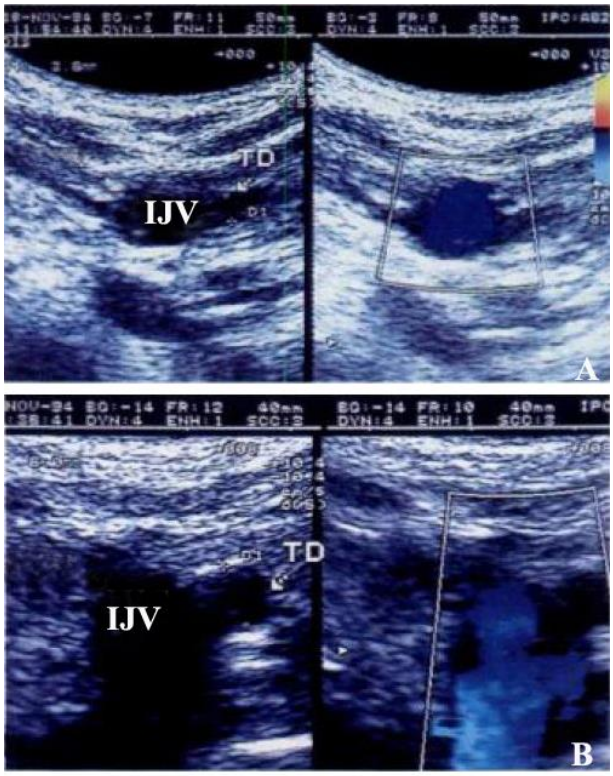

Prof. Bolondi and his team first used EUS to detect portal hypertension and evaluate esophageal varices [(39, 40)]. They tried to make sonographic evaluation of the portal venous system after elective endoscopic sclerotherapy of esophageal varices [(41)]. For other abdominal vascular diseases, they also used dynamic ultrasonography to visualize aneurysm of the splenic artery [(42)] and to check the patency of porto-systemic surgical shunts [(43)(44)]. Prof. Bolondi's commitment to the understanding of portal hypertension and chronic liver disease by using ultrasound and Doppler-ultrasound is shown by a large number of papers published in the following decade, including US use to detect unusual spontaneous portosystemic shunts associated with uncomplicated portal hypertension [(45)], to evaluate the morphological bases of splenic circulation in congestive splenomegaly [(46)],

to examine the caliber of splenic and hepatic arteries and spleen size in cirrhosis of different etiology [(47)], to assess the hepatic artery resistance in portal vein thrombosis [(48)], diagnosis and monitoring of portohepatic vascular pathology and liver disease [(49)], to describe Doppler findings in splenic arteriovenous fistula [(50)] and to describe intrahepatic artery pseudoaneurysm [(51)] and cardiac abnormalities in cirrhosis [(52)] and other findings in diffuse liver diseases [(53-59)].

Focal liver lesions

Prof. Bolondi and his team shaped the applications of ultrasound to identify and characterize focal liver lesions since very early times [(60-65)]. His interest was broad, ranging from the diagnosis of hepatic haemangiomas [(66)] to that of malignancies in patients with cirrhosis [(67)]. [Figure 12-13]

Figure 22 Liver cyst by longitudinal scan. Compound Grey scale (1976)

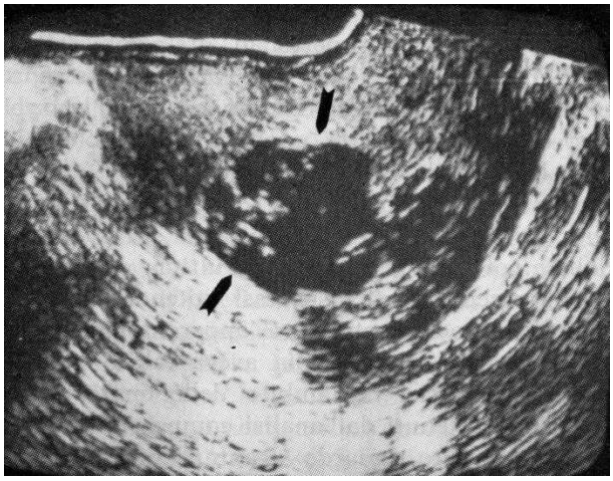

Figure 13 Longitudinal scan of the liver and kidney- Compound grey scale (1976)

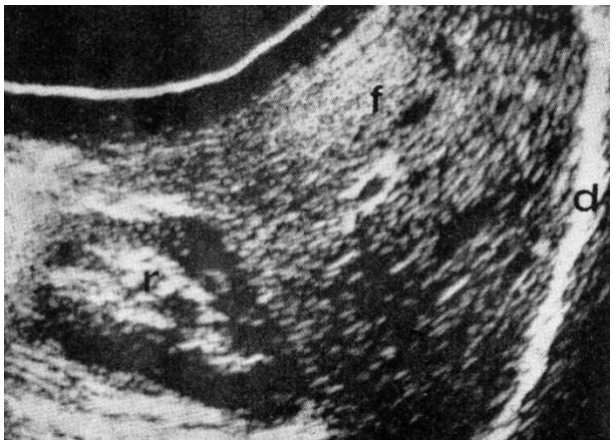

Hepatocellular carcinoma

Hepatocellular carcinoma (HCC) is a major cause of death in liver cirrhosis patients. Early diagnosis and treatment of HCC are expected to improve survival of patients [(68-72)]. Prof. Bolondi reported the relationship between alpha-fetoprotein serum levels, tumour volume and growth rate of HCC in a western population [(73, 74)]. He assessed between March 1989 and November 1991 the cost effectiveness of a surveillance programme in a cohort of 313 patients with liver cirrhosis for the early diagnosis and treatment of HCC [(74, 75)].

In a large retrospective study on 2091 biopsies, Prof. Bolondi investigated ultrasound-guided fine-needle biopsy of focal liver lesions [(76)], proving that the diagnostic accuracy of fine-needle biopsies was very high (only one false positive was observed), both for aspiration biopsy (93.4%) and for cutting biopsy (95.1%) [(76-79)].

To define indications for percutaneous ethanol injection (PEI) in patients with HCC and cirrhosis, Prof. Bolondi and his team made a long-term follow-up of 746 patients between 1985 to 1993 [(80)]. They indicated that PEI is safe, effective, and repeatable and had low cost. Survival after PEI was comparable to that after surgery [(80-82)]. These findings strengthened the use of US-guided locoregional therapies for HCC.

Prof. Bolondi and his team made some breakthrough discoveries in the liver transplantation area. They prospectively evaluated the reliability of ultrasound screening of liver and kidney donors [(83)]. They also investigated the long-term changes induced by orthotopic liver transplantation (OLT) on several hemodynamic parameters [(84, 85)]. They first reported in Hepatology in 1999 that systemic, renal, and splanchnic circulatory alterations of cirrhosis

are restored to normal after OLT [(86)]. They published their results about liver transplantation for HCC in patients initially outside of the Milan selection criteria [(87)].

Contrast enhanced ultrasound was a new imaging method at that time. Prof. Bolondi first evaluated the use of Levovist to assess splanchnic hemodynamics in cirrhotic patients [(88)] and in liver transplantation, and to assess the conservative management of post-transplant intra-hepatic pseudo-aneurysm [(89)]. Diagnosis of HCC relies strongly on the detection of hypervascularity in the arterial phase. Previously spiral computed tomography (CT) was the most widely used method [(90)]. Prof. Bolondi first investigated the usefulness of low mechanical index harmonic ultrasound, using a second generation contrast enhanced technique in the assessment of vascular pattern of HCC shown to be hypervascular at spiral CT [Figure 14]. Contrast enhanced ultrasound showed good diagnostic agreement with spiral CT in hypervascular HCC and might be proposed for the immediate vascular characterization of nodules detected at US and used as second imaging technique to confirm hypervascularity in cirrhotic nodules [(90)].

Figure 14 Vascular enhancement pattern of HCC using contrast enhanced ultrasound.

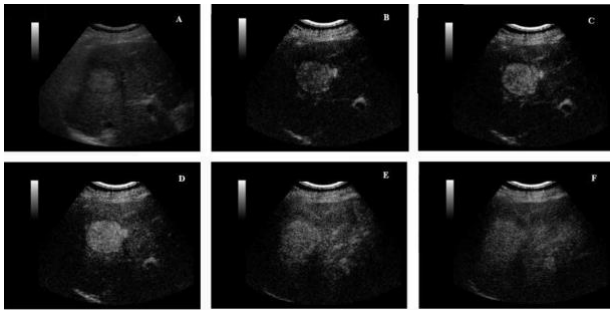

Prof. Bolondi indicated the value and limitation of the different Doppler ultrasound modalities in assessment of vascular patterns of small liver mass lesions [(91, 92)]. In a prospective study, Prof. Bolondi examined the impact of arterial hypervascularity, as established by the European Association for the Study of the Liver (EASL) recommendations, as a criterion for characterizing small (1 – 3 cm) nodules in liver cirrhosis [Figure 12] [(93, 94)]. They suggested in their paper published in Hepatology that the noninvasive EASL criteria for diagnosis of HCC are satisfied in only 61% of small nodules in liver cirrhosis. Any nodule larger than 2 cm should be regarded as highly suspicious for HCC [(95, 96)]. They

made cost analysis of recall strategies for non-invasive diagnosis of small HCC [(97)]. [Figure 15-16]

Figure 15 Hypoechoic liver metastases by longitudinal scan. Compound Grey scale (1976)

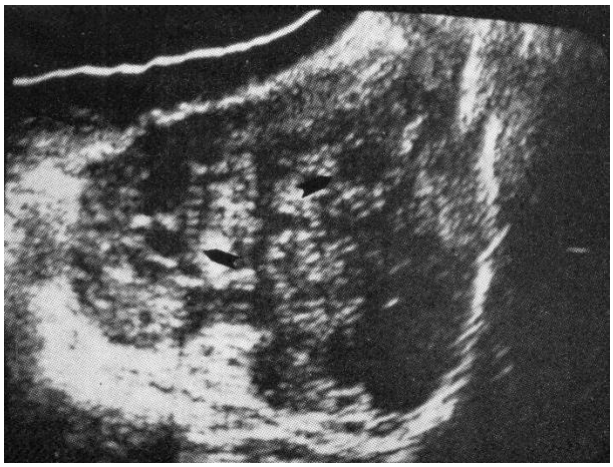

Figure 16 Hypoechoic liver metastases (m) by longitudinal scan. Compound Grey scale (1976)

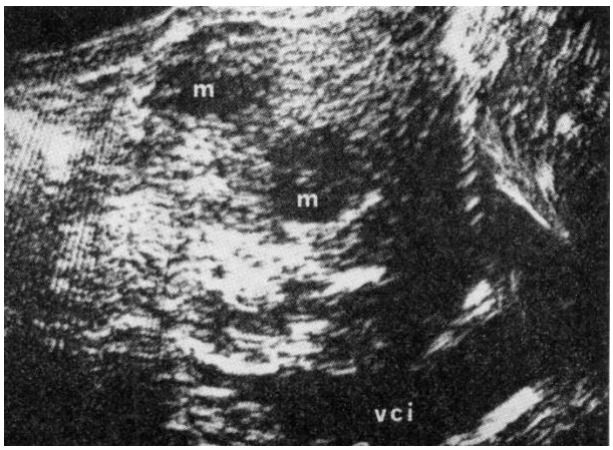

Prof. Bolondi and his team also used real-time contrast enhanced harmonic sonography at low acoustic energy to evaluate liver metastases from rectal carcinoma [(98)],

gastrointestinal cancer [(99)] and metastatic portal vein thrombosis [(100, 101)]. They also differentiated between various liver tumours [(102-117)] and made quantitative analysis of liver tumour perfusion by contrast enhanced ultrasound [(118)]. They explored some new application of real-time contrast enhanced ultrasound, such as for detection of peritoneal-pleural communications in hepatic hydrothorax [(119)] and for the evaluation of coil embolization of splenic artery aneurysm [(120)]. [Figure 17]

Prof. Bolondi and his team evaluated the safety of Sonovue in abdominal applications in a retrospective analysis of 23,188 investigations [(121)]. He published the first guideline for the use of contrast agents in ultrasound in January 2004 [(122)] and position paper of the Italian Association for the Study of the Liver (AISF) for the multidisciplinary clinical approach to HCC [(123)]. Luigi Bolondi's team also compared international guidelines for noninvasive diagnosis of HCC [(124)] and updated the contrast enhanced ultrasound guideline in 2008 [(125)].

Figure 17 Typical appearance of HCC (arrows) on contrast enhanced ultrasound.

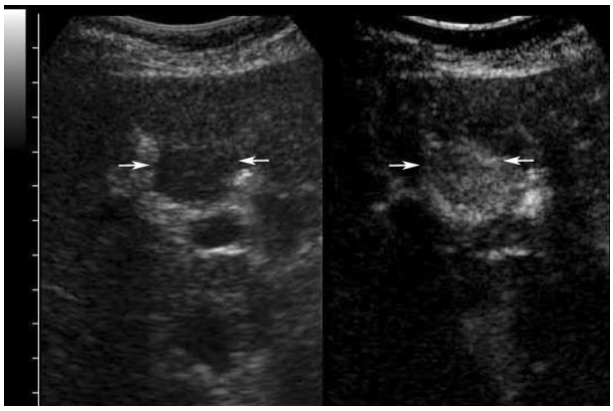

Luigi Bolondi's contribution to hepatology and medicine goes far beyond ultrasound. In the field of advanced HCC, he was one of the authors of a large randomized controlled trial proving that systemic therapy using a multikinase inhibitor (Sorafenib) can improve survival [(126-133)]. The results were published in the New England Journal of Medicine [(126)].

The intermediate stage of HCC comprises a highly heterogeneous patient population and, therefore, poses unique challenges for therapeutic management, different from the early and advanced stages [(134, 135)]. In April 2012, Prof. Bolondi joined a panel of experts and

discussed unresolved issues surrounding the application of guidelines when managing patients with intermediate HCC. The meeting explored the applicability of a subclassification system for intermediate HCC patients to tailor therapeutic interventions based on the evidence available to date and expert opinion [(135)].

Pancreatic disease

Prof. Bolondi and his team explored the application of ultrasound in pancreatic or Whipple's disease early on [(136, 137)]. They first made an evaluation of echography in the diagnosis of pancreatic disease in 1975 [(1)] [Figure 18-19].

Figure 18 Enlarged head of the Pancreas - Longitudinal scan - Compound bistable (1974)

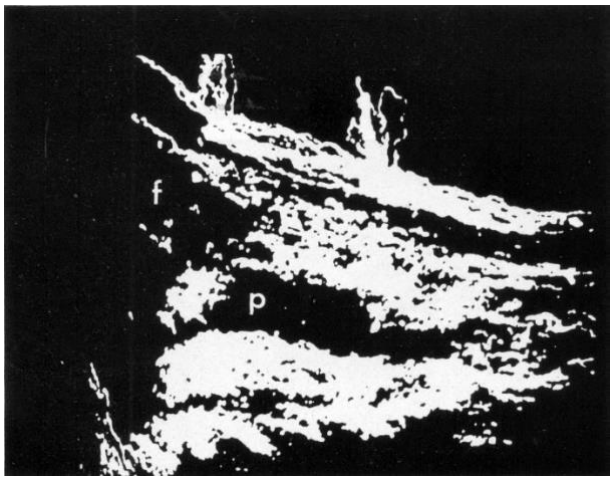

Figure 19 Enlarged head of the Pancreas - Transverse scan - Compound bistable (1974)

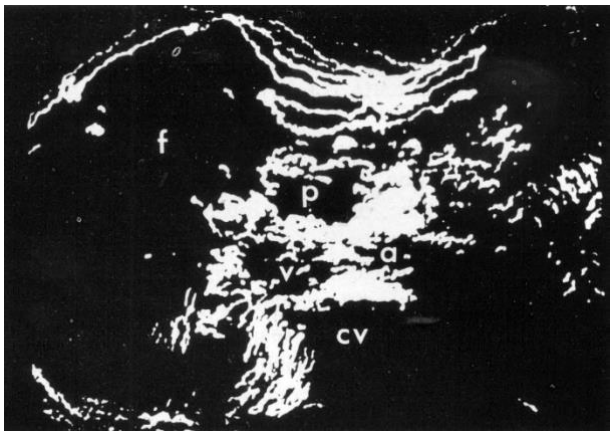

After that, they used ultrasound in diagnosis and treatment of chronic pancreatitis [(137-145)], to evaluate the therapeutic effect of a pharmacological combination of choleretics and digestive enzymes in exocrine pancreatic insufficiency [(146)], to make diagnosis of islet cell tumour by means of endoscopic ultrasonography [(147)] and pseudocysts [Figure 20-21]. They also used contrast enhanced ultrasound to evaluate the extramedullary hematopoiesis presenting as a presacral mass [(148)].

Figure 20 Pancreatic pseudocyst (pc) - Transverse scan - Compound bistable (1974)

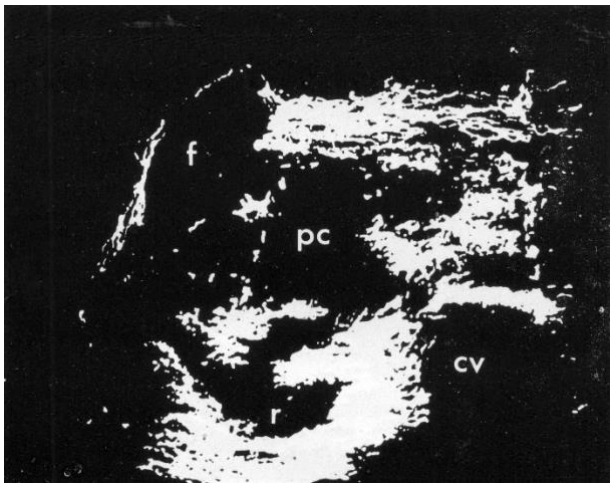

Figure 21 Pancreatic pseudocyst (pc) - Longitudinal scan - Compound bistable (1974)

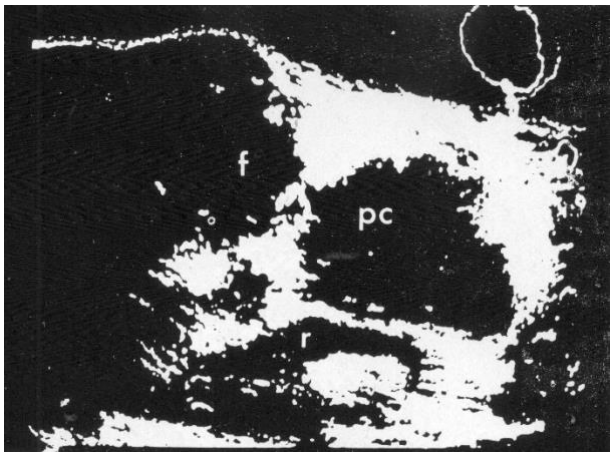

For ultrasound imaging of the pancreas, the body is the best visualized part of the pancreas, however, the head and the tail are always obscured by gas in the stomach or duodenum. In order to improve the pancreatic ultrasound imaging, Prof. Bolondi stimulated pancreatic juice secretion by a standard dose of intravenous secretin in 24 normal subjects. They observed that 4 to 5 minutes after hormone administration pancreatic juice outflow into the duodenum generated a fluid-filled echofree area around the head of the pancreas, allowing excellent visualization of its boundaries and other channel structures [Figure 22]. This method was suggested to be utilized in selected patients whenever a pathological condition of the pancreatic head region is suspected [(149, 150)].

Figure 22 A figure in Prof. Bolondi's paper showed Improvement of pancreatic head visualization after secretin-induced pancreatic secretion [(149)].

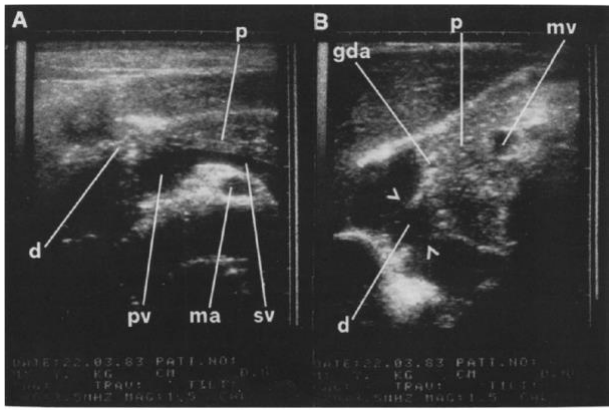

Interventional procedures

In 1978, Prof. Bolondi used ultrasonography in the diagnosis of cholestatic jaundice [(3)]. He compared ultrasound findings with endoscopic retrograde cholangio-pancreatography (ERCP) [(151)]. Ever since then, endoscopic treatment of obstructive cholangitis were explored and applied to daily routine [(152)]. They used endoscopic retrograde cholangiography (ERC) also through artificial endoscopic choledocho-duodenal fistula [Figure 23]. They concluded that this new method might permit an endoscopic choledocho-duodenostomy for choledocholithiasis in cases of unsuccessful endoscopic papillo-sphincterotomy [(153)]. They also used diathermy ERCP as an alternative method for ERCP in jaundiced patients [(154)].

Figure 23 Endoscopic retrograde cholangiography performed through a fistula. The obstruction of the distal end of the common bile duct due to a carcinoma of the head of the pancreas is shown (arrow).

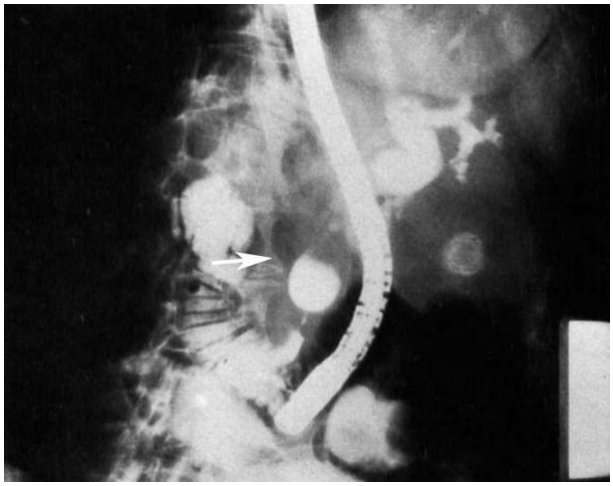

Other publications

Prof. Bolondi also evaluated the diagnostic opportunities of ultrasound in renal diseases [(155, 156)], the inhibitory effect of atropine on cholecystokinin-induced gallbladder contraction and emptying [(157-159)], knowledge in the acute cholecystitis caused by gallbladder stones and sludge [(160-162)], non-invasive assessment by Doppler ultrasound of splanchnic hemodynamics in inflammatory bowel disease [(163)], evaluation of changes in

mesenteric venous flow due to celiac sprue [(164)], diagnosis and follow-up by duplex and color Doppler for extracranial vertebral artery dissection with spontaneous recovery [(165)] and many other subjects.

He discovered sonographic findings in abdominal hereditary angioedema [(166)], the sonographic diagnosis of adult intussusception [(167)], and usefulness of ultrasound elastography in the assessment of liver fibrosis or stiffness [(168-174)].

Prof. Bolondi participated in many survey, e.g., a survey conducted by the Italian Society for Ultrasound in Medicine and Biology (SIUMB) reported knowledge of the bio-effects of ultrasound among physicians performing clinical ultrasonography [(175)].

Intraoperative ultrasonography was first used in 37 patients during surgery for suspected liver tumours. This new imaging techinique facilitated the diagnosis of small liver tumours and also aided the surgeon in his choice of technique, especially in cases of cirrhosis of the liver. A resection can be avoided altogether when multiple lesions are involved, or echo-guided subsegmentary resections can be performed in cirrhotic livers when a less extended resection is required. This technique makes it possible to establish the relationship between the tumour and intrahepatic vessels, thus preventing vascular injury and making radical hepatic resection safer [(176-178)].

References

1. Fontana G, Bolondi L, Conti M, Plicchi G, Gullo L, Caletti GC, Labo G. An evaluation of echography in the diagnosis of pancreatic disease. Gut 1976;17:228-234.
2. Bolondi L, Gandolfi L. Ultrasonography in assessment of portal venous system. Lancet 1978;1:656-657.
3. Bolondi L, Gandolfi L, Rossi A, Caletti GC, Fontana G, Labo G. Ultrasound in the diagnosis of cholestatic jaundice. Am J Gastroenterol 1979;71:168-176.
4. Bolondi L, Bortolotti M, Santi V, Calletti T, Gaiani S, Labo G. Measurement of gastric emptying time by real-time ultrasonography. Gastroenterology 1985;89:752-759.
5. Bortolotti M, Bolondi L, Santi V, Sarti P, Brunelli F, Barbara L. Patterns of gastric emptying in dysmotility-like dyspepsia. Scand J Gastroenterol 1995;30:408-410.
6. Bolondi L, Casanova P, Santi V, Caletti G, Barbara L, Labo G. The sonographic appearance of the normal gastric wall: an in vitro study. Ultrasound Med Biol 1986;12:991-998.
7. Caletti G, Bolondi L, Labo G. Ultrasonic endoscopy--the gastrointestinal wall. Scand J Gastroenterol Suppl 1984;102:5-8.
8. Caletti G, Bolondi L, Labo G. Anatomical aspects in ultrasonic endoscopy for the stomach. Scand J Gastroenterol Suppl 1984;94:34-42.

9. Bolondi L, Caletti G, Casanova P, Villanacci V, Grigioni W, Labo G. Problems and variations in the interpretation of the ultrasound feature of the normal upper and lower GI tract wall. Scand J Gastroenterol Suppl 1986;123:16-26.
10. Caletti GC, Bertoni F, Bolondi L, Costa PL, Fontana G. [Enterorrhagia of ulcerated Meckel's diverticulum from the point of view of current diagnostic technics. Report of a case]. Arch De Vecchi Anat Patol 1973;59:111-126.
11. Bolondi L, Ferrentino M, Trevisani F, Bernardi M, Gasbarrini G. Sonographic appearance of pseudomembranous colitis. J Ultrasound Med 1985;4:489-492.
12. Bolondi L, Casanova P, Caletti GC, Grigioni W, Zani L, Barbara L. Primary gastric lymphoma versus gastric carcinoma: endoscopic US evaluation. Radiology 1987;165:821-826.
13. Caletti GC, Lorena Z, Bolondi L, Guizzardi G, Brocchi E, Barbara L. Impact of endoscopic ultrasonography on diagnosis and treatment of primary gastric lymphoma. Surgery 1988;103:315-320.
14. Caletti G, Zani L, Bolondi L, Brocchi E, Rollo V, Barbara L. Endoscopic ultrasonography in the diagnosis of gastric submucosal tumor. Gastrointest Endosc 1989;35:413-418.
15. Bolondi L, De Giorgio R, Santi V, Paparo GF, Pileri S, Di Febo G, Caletti GC, et al. Primary non-Hodgkin's T-cell lymphoma of the esophagus. A case with peculiar endoscopic ultrasonographic pattern. Dig Dis Sci 1990;35:1426-1430.
16. Bolondi L, Gandolfi L, Arienti V, Caletti GC, Corcioni E, Gasbarrini G, Labo G. Ultrasonography in the diagnosis of portal hypertension: diminished response of portal vessels to respiration. Radiology 1982;142:167-172.
17. Gaiani S, Bolondi L, Li Bassi S, Zironi G, Siringo S, Barbara L. Prevalence of spontaneous hepatofugal portal flow in liver cirrhosis. Clinical and endoscopic correlation in 228 patients. Gastroenterology 1991;100:160-167.
18. Piscaglia F, Donati G, Serra C, Muratori R, Solmi L, Gaiani S, Gramantieri L, et al. Value of splanchnic Doppler ultrasound in the diagnosis of portal hypertension. Ultrasound Med Biol 2001;27:893-899.
19. Bolondi L, Caletti G, Brocchi E, Ferrentino M, Calcamuggi G, Casanova P, Gasbarrini G, et al. Ultrasonographic findings in portal hypertension: correlation with the presence and size of oesophageal varices. Ultrasound Med Biol 1983;Suppl 2:499-503.
20. Zironi G, Cavalli G, Casali A, Piscaglia F, Gaiani S, Siringo S, Sofia S, et al. Sonographic assessment of the distal end of the thoracic duct in healthy volunteers and in patients with portal hypertension. AJR Am J Roentgenol 1995;165:863-866.
21. Piscaglia F, Donati G, Cecilioni L, Celli N, Stagni B, Pini P, Gaiani S, et al. Influence of the spleen on portal haemodynamics: a non-invasive study with Doppler ultrasound in chronic liver disease and haematological disorders. Scand J Gastroenterol 2002;37:1220-1227.
22. Piscaglia F, Cecilioni L, Gaiani S, Bolondi L. Portal pressure and Doppler. Ultrasound Med Biol 2003;29:495-496.
23. Bolondi L, Gaiani S, Barbara L. Accuracy and reproducibility of portal flow measurement by Doppler US. J Hepatol 1991;13:269-273.
24. Bolondi L, Gaiani S, Li Bassi S, Zironi G, Bonino F, Brunetto M, Barbara L. Diagnosis of Budd-Chiari syndrome by pulsed Doppler ultrasound. Gastroenterology 1991;100:1324-1331.
25. Valgimigli M, Piscaglia F, Gaiani S, Bolondi L. Splanchnic arterial Doppler parameters in portal hypertension. Hepatology 1999;29:1610.

26. Siringo S, Piscaglia F, Zironi G, Sofia S, Gaiani S, Zammataro M, Bolondi L. Influence of esophageal varices and spontaneous portal-systemic shunts on postprandial splanchnic hemodynamics. Am J Gastroenterol 2001;96:550-556.
27. Sabba C, Merkel C, Zoli M, Ferraioli G, Gaiani S, Sacerdoti D, Bolondi L. Interobserver and interequipment variability of echo-Doppler examination of the portal vein: effect of a cooperative training program. Hepatology 1995;21:428-433.
28. Bolondi L, Li Bassi S, Gaiani S, Zironi G, Benzi G, Santi V, Barbara L. Liver cirrhosis: changes of Doppler waveform of hepatic veins. Radiology 1991;178:513-516.
29. Gaiani S, Bolondi L, Fenyves D, Zironi G, Rigamonti A, Barbara L. Effect of propranolol on portosystemic collateral circulation in patients with cirrhosis. Hepatology 1991;14:824-829.
30. Sacerdoti D, Gaiani S, Buonamico P, Merkel C, Zoli M, Bolondi L, Sabba C. Interobserver and interequipment variability of hepatic, splenic, and renal arterial Doppler resistance indices in normal subjects and patients with cirrhosis. J Hepatol 1997;27:986-992.
31. Piscaglia F, Gaiani S, Bolondi L. Diagnosis of cirrhosis and portal hypertension. Am J Gastroenterol 1998;93:1598-1599.
32. Zoli M, Merkel C, Sabba C, Sacerdoti D, Gaiani S, Ferraioli G, Bolondi L. Interobserver and inter-equipment variability of echo-Doppler sonographic evaluation of the superior mesenteric artery. J Ultrasound Med 1996;15:99-106.
33. Piscaglia F, Gaiani S, Siringo S, Gramantieri L, Serra C, Bolondi L. Duplex-Doppler evaluation of the effects of propranolol and isosorbide-5-mononitrate on portal flow and splanchnic arterial circulation in cirrhosis. Aliment Pharmacol Ther 1998;12:475-481.
34. Piscaglia F, Gaiani S, Calderoni D, Donati G, Celli N, Gramantieri L, Crespi C, et al. Influence of liver fibrosis on hepatic artery Doppler resistance index in chronic hepatitis of viral origin. Scand J Gastroenterol 2001;36:647-652.
35. Bolondi L, Li Bassi S, Gaiani S, Barbara L. Doppler flowmetry in portal hypertension. J Gastroenterol Hepatol 1990;5:459-467.
36. Piscaglia F, Gaiani S, Gramantieri L, Zironi G, Siringo S, Bolondi L. Superior mesenteric artery impedance in chronic liver diseases: relationship with disease severity and portal circulation. Am J Gastroenterol 1998;93:1925-1930.
37. Piscaglia F, Gaiani S, Donati G, Masi L, Bolondi L. Doppler evaluation of the effects of pharmacological treatment of portal hypertension. Ultrasound Med Biol 1999;25:923-932.
38. Bolondi L, Gaiani S, Li Bassi S, Zironi G, Casanova P, Barbara L. Effect of secretin on portal venous flow. Gut 1990;31:1306-1310.
39. Caletti GC, Bolondi L, Zani L, Brocchi E, Guizzardi G, Labo G. Detection of portal hypertension and esophageal varices by means of endoscopic ultrasonography. Scand J Gastroenterol Suppl 1986;123:74-77.
40. Caletti GC, Bolondi L, Zani L, Labo G. Technique of endoscopic ultrasonography investigation: esophagus, stomach and duodenum. Scand J Gastroenterol Suppl 1986;123:1-5.
41. Caletti GC, Brocchi E, Zani L, Bolondi L, Baraldini M, Rollo V, Barbara L. Sonographic evaluation of the portal venous system after elective endoscopic sclerotherapy of esophageal varices. Surg Endosc 1987;1:165-167.
42. Bolondi L, Casanova P, Arienti V, Testa S, Gaiani S, Labo G. A case of aneurysm of the splenic artery visualized by dynamic ultrasonography. Br J Radiol 1981;54:1109-1111.
43. Mazziotti A, Cavallari A, Antonini L, Bellusci R, Bolondi L, Papa V, Rossi C, et al. [Control of the patency of porto-systemic anastomoses]. Minerva Chir 1981;36:433-462.

44. Bolondi L, Mazziotti A, Arienti V, Casanova P, Gasbarrini G, Cavallari A, Bellusci R, et al. Ultrasonographic study of portal venous system in portal hypertension and after portosystemic shunt operations. Surgery 1984;95:261-269.
45. Di Candio G, Campatelli A, Mosca F, Santi V, Casanova P, Bolondi L. Ultrasound detection of unusual spontaneous portosystemic shunts associated with uncomplicated portal hypertension. J Ultrasound Med 1985;4:297-305.
46. Re G, Casali A, Cavalli D, Guida G, Toni R, Bolondi L, Cavalli G. Morphological bases of splenic circulation in congestive splenomegaly. Haematologica 1985;70:283-290.
47. Bolondi L, Zironi G, Gaiani S, Li Bassi S, Benzi G, Barbara L. Caliber of splenic and hepatic arteries and spleen size in cirrhosis of different etiology. Liver 1991;11:198-205.
48. Piscaglia F, Gaiani S, Zironi G, Siringo S, Bolondi L. Hepatic artery resistance in portal vein thrombosis. Radiology 1996;200:285-286.
49. Bolondi L, Gaiani S, Gebel M. Portohepatic vascular pathology and liver disease: diagnosis and monitoring. Eur J Ultrasound 1998;7 Suppl 3:S41-52.
50. Piscaglia F, Valgimigli M, Serra C, Donati G, Gramantieri L, Bolondi L. Duplex Doppler findings in splenic arteriovenous fistula. J Clin Ultrasound 1998;26:103-105.
51. Zironi G, Piscaglia F, Gaiani S, Masi L, Bolondi L. Intrahepatic artery pseudoaneurysm: a possible complication of blind thoracentesis. J Clin Ultrasound 1999;27:151-155.
52. Piscaglia F, Serra C, Celli N, Donati G, Gaiani S, Bolondi L. Cardiac abnormalities in cirrhosis. Am J Gastroenterol 2001;96:2503-2505.
53. Toni R, Bolondi L, Gaiani S, Re G, Calabrese L, Cavalli G, Labo G. Accessory ultrasonographic findings in chronic liver disease: diameter of splenic and hepatic arteries, fasting gallbladder volume, and course of left portal vein. J Clin Ultrasound 1985;13:611-618.
54. Gaiani S, Bolondi L, Li Bassi S, Santi V, Zironi G, Barbara L. Effect of meal on portal hemodynamics in healthy humans and in patients with chronic liver disease. Hepatology 1989;9:815-819.
55. Siringo S, Bolondi L, Gaiani S, Sofia S, Di Febo G, Zironi G, Rigamonti A, et al. The relationship of endoscopy, portal Doppler ultrasound flowmetry, and clinical and biochemical tests in cirrhosis. J Hepatol 1994;20:11-18.
56. Gaiani S, Gramantieri L, Venturoli N, Piscaglia F, Siringo S, D'Errico A, Zironi G, et al. What is the criterion for differentiating chronic hepatitis from compensated cirrhosis? A prospective study comparing ultrasonography and percutaneous liver biopsy. J Hepatol 1997;27:979-985.
57. Piscaglia F, Gaiani S, Zironi G, Gramantieri L, Casali A, Siringo S, Serra C, et al. Intra- and extrahepatic arterial resistances in chronic hepatitis and liver cirrhosis. Ultrasound Med Biol 1997;23:675-682.
58. Piscaglia F, Zironi G, Gaiani S, Ferlito M, Rapezzi C, Siringo S, Gaia C, et al. Relationship between splanchnic, peripheral and cardiac haemodynamics in liver cirrhosis of different degrees of severity. Eur J Gastroenterol Hepatol 1997;9:799-804.
59. Siringo S, Bolondi L, Gaiani S, Sofia S, Zironi G, Rigamonti A, Di Febo G, et al. Timing of the first variceal hemorrhage in cirrhotic patients: prospective evaluation of Doppler flowmetry, endoscopy and clinical parameters. Hepatology 1994;20:66-73.
60. Gandolfi L, Bolondi L, Rossi A, Fontana G. [Role of grey scale echotomography in the diagnosis of liver diseases]. Recenti Prog Med 1977;63:527-538.
61. Gandolfi L, Rossi A, Bolondi L, Solmi L. [Use of gray-scale echography in the diagnosis of hepatic lesions--comparison with laparoscopy]. G Clin Med 1977;58:290-292.
62. Gozzetti G, Mazziotti A, Cavallari A, Bellusci R, Bolondi L, Grigioni W, Grazi GL. Hepatic resection for tumours in cirrhotic livers. Int Surg 1987;72:82-86.

63. Bolondi L, Piscaglia F, Gatta A, Salerno F, Bernardi M, Ascione A, Ferrau O, et al. Effect of potassium canrenoate, an anti-aldosterone agent, on incidence of ascites and variceal progression in cirrhosis. Clin Gastroenterol Hepatol 2006;4:1395-1402.
64. Di Stefano G, Fiume L, Baglioni M, Bolondi L, Chieco P, Kratz F, Pariali M, et al. Efficacy of doxorubicin coupled to lactosaminated albumin on rat hepatocellular carcinomas evaluated by ultrasound imaging. Dig Liver Dis 2008;40:278-284.
65. Bolondi L, Gramantieri L. From liver cirrhosis to HCC. Intern Emerg Med 2011;6 Suppl 1:93-98.
66. Gandolfi L, Solmi L, Bolondi L, Rossi A, Casanova P, Leo P. The value of ultrasonography in the diagnosis of hepatic haemangiomas. Eur J Radiol 1983;3:222-226.
67. Gaiani S, Volpe L, Piscaglia F, Bolondi L. Vascularity of liver tumours and recent advances in doppler ultrasound. J Hepatol 2001;34:474-482.
68. Gaiani S, Li Bassi S, Zironi G, Bolondi L, Barbara L. Caution in the interpretation of Doppler signals of HCC. Gastroenterology 1990;99:1860.
69. Chieco P, Stecca B, Bolondi L, Melchiorri C, Gaiani S, Barbara L. Cytochemical detection of a class 3 aldehyde dehydrogenase in human hepatocellular carcinoma. Liver 1995;15:87-92.
70. Bolondi L, Gramantieri L, Chieco P, Melchiorri C, Trere D, Stecca B, Derenzini M, et al. Enzymatic cytochemistry, DNA ploidy and AgNOR quantitation in hepatocellular nodules of uncertain malignant potential in liver cirrhosis. Dig Dis Sci 1996;41:800-808.
71. Trere D, Gramantieri L, Siringo S, Melchiorri C, Barbara L, Bolondi L, Derenzini M. In hepatocellular carcinoma AgNOR protein expression correlates with tumour mass doubling time. J Hepatol 1996;24:60-65.
72. Piscaglia F, Bolondi L. Recent advances in the diagnosis of hepatocellular carcinoma. Hepatol Res 2007;37 Suppl 2:S178-192.
73. Bolondi L, Benzi G, Santi V, Gaiani S, Li Bassi SL, Zironi G, Mazziotti A, et al. Relationship between alpha-fetoprotein serum levels, tumour volume and growth rate of hepatocellular carcinoma in a western population. Ital J Gastroenterol 1990;22:190-194.
74. Bolondi L, Sofia S, Siringo S, Gaiani S, Casali A, Zironi G, Piscaglia F, et al. Surveillance programme of cirrhotic patients for early diagnosis and treatment of hepatocellular carcinoma: a cost effectiveness analysis. Gut 2001;48:251-259.
75. Lencioni R, Piscaglia F, Bolondi L. Contrast-enhanced ultrasound in the diagnosis of hepatocellular carcinoma. J Hepatol 2008;48:848-857.
76. Buscarini L, Fornari F, Bolondi L, Colombo P, Livraghi T, Magnolfi F, Rapaccini GL, et al. Ultrasound-guided fine-needle biopsy of focal liver lesions: techniques, diagnostic accuracy and complications. A retrospective study on 2091 biopsies. J Hepatol 1990;11:344-348.
77. Bolondi L, Gaiani S, Benzi G, Zironi G, Rigamonti A, Fusconi F, Barbara L. Ultrasonography and guided biopsy in the diagnosis of hepatocellular carcinoma. Ital J Gastroenterol 1992;24:46-49.
78. Melchiorri C, Bolondi L, Chieco P, Pagnoni M, Gramantieri L, Barbara L. Diagnostic and prognostic value of DNA ploidy and cell nuclearity in ultrasound-guided liver biopsies. Cancer 1994;74:1713-1719.
79. Faccioli S, Chieco P, Gramantieri L, Stecca BA, Bolondi L. Cytometric measurement of cell proliferation in echo-guided biopsies from focal lesions of the liver. Mod Pathol 1996;9:120-125.
80. Livraghi T, Giorgio A, Marin G, Salmi A, de Sio I, Bolondi L, Pompili M, et al. Hepatocellular carcinoma and cirrhosis in 746 patients: long-term results of percutaneous ethanol injection. Radiology 1995;197:101-108.

81. Livraghi T, Salmi A, Bolondi L, Marin G, Arienti V, Monti F, Vettori C. Small hepatocellular carcinoma: percutaneous alcohol injection--results in 23 patients. Radiology 1988;168:313-317.
82. Livraghi T, Bolondi L, Lazzaroni S, Marin G, Morabito A, Rapaccini GL, Salmi A, et al. Percutaneous ethanol injection in the treatment of hepatocellular carcinoma in cirrhosis. A study on 207 patients. Cancer 1992;69:925-929.
83. Venturoli N, Costa AN, Ridolfi L, Pugliese MR, Taddei S, Petrini F, Bolondi L, et al. Reliability of ultrasound screening of liver and kidney donors: a retrospective study. Prog Transplant 2000;10:182-185.
84. Golfieri R, Giampalma E, Fusco F, Grazi G, Ercolani G, Sama C, Morelli C, et al. Orthotopic liver transplantation (OLT): Contribution of imaging and interventional radiology in preparing the transplantation and managing complications. Part 2: Post-OLT complications and their treatment. Radiol Med 2005;110:433-481; quiz 482-433.
85. Golfieri R, Giampalma E, Fusco F, Grazi G, Ercolani G, Sama C, Morelli C, et al. Orthotopic liver transplantation (OLT): Contribution of diagnostic imaging and interventional radiology in preparing the transplantation and managing complications. Part 1: Indications, surgical technique, diagnostic imaging and interventional radiology before transplantation from cadaveric and living donor. Radiol Med 2005;110:391-430; quiz 431-392.
86. Piscaglia F, Zironi G, Gaiani S, Mazziotti A, Cavallari A, Gramantieri L, Valgimigli M, et al. Systemic and splanchnic hemodynamic changes after liver transplantation for cirrhosis: a long-term prospective study. Hepatology 1999;30:58-64.
87. Ravaioli M, Grazi GL, Piscaglia F, Trevisani F, Cescon M, Ercolani G, Vivarelli M, et al. Liver transplantation for hepatocellular carcinoma: results of down-staging in patients initially outside the Milan selection criteria. Am J Transplant 2008;8:2547-2557.
88. Gaiani S, Serra C, Piscaglia F, Celli N, Rasciti L, Miglioli M, Bolondi L. Effect of Levovist on splanchnic hemodynamics in cirrhotic patients. Ultrasound Med Biol 2003;29:643-648.
89. Piscaglia F, Cecilioni L, Gaiani S, Rossi C, Losinno F, Cescon M, Camaggi V, et al. Use of perfusional angiosonography in liver transplantation and conservative management of post-transplant intra-hepatic pseudo-aneurysm. Transpl Int 2004;17:634-638.
90. Gaiani S, Celli N, Piscaglia F, Cecilioni L, Losinno F, Giangregorio F, Mancini M, et al. Usefulness of contrast-enhanced perfusional sonography in the assessment of hepatocellular carcinoma hypervascular at spiral computed tomography. J Hepatol 2004;41:421-426.
91. Gaiani S, Casali A, Serra C, Piscaglia F, Gramantieri L, Volpe L, Siringo S, et al. Assessment of vascular patterns of small liver mass lesions: value and limitation of the different Doppler ultrasound modalities. Am J Gastroenterol 2000;95:3537-3546.
92. Leoni S, Piscaglia F, Righini R, Bolondi L. Management of small hepatocellular carcinoma. Acta Gastroenterol Belg 2006;69:230-235.
93. Leoni S, Piscaglia F, Golfieri R, Camaggi V, Vidili G, Pini P, Bolondi L. The impact of vascular and nonvascular findings on the noninvasive diagnosis of small hepatocellular carcinoma based on the EASL and AASLD criteria. Am J Gastroenterol 2010;105:599-609.
94. Granito A, Galassi M, Piscaglia F, Romanini L, Lucidi V, Renzulli M, Borghi A, et al. Impact of gadoxetic acid (Gd-EOB-DTPA)-enhanced magnetic resonance on the non-invasive diagnosis of small hepatocellular carcinoma: a prospective study. Aliment Pharmacol Ther 2013;37:355-363.
95. Bolondi L, Gaiani S, Celli N, Golfieri R, Grigioni WF, Leoni S, Venturi AM, et al. Characterization of small nodules in cirrhosis by assessment of vascularity: the problem of hypovascular hepatocellular carcinoma. Hepatology 2005;42:27-34.

96. Golfieri R, Marini E, Bazzocchi A, Fusco F, Trevisani F, Sama C, Mazzella G, et al. Small (<or=3 cm) hepatocellular carcinoma in cirrhosis: the role of double contrast agents in MR imaging vs. multidetector-row CT. Radiol Med 2009;114:1239-1266.
97. Piscaglia F, Leoni S, Cabibbo G, Borghi A, Imbriaco G, Golfieri R, Bolondi L. Cost analysis of recall strategies for non-invasive diagnosis of small hepatocellular carcinoma. Dig Liver Dis 2010;42:729-734.
98. Piscaglia F, Gaiani S, Tamberi S, Celli N, Cecilioni L, Gramantieri L, Bolondi L. Liver metastases from rectal carcinoma: disease progression during chemotherapy despite loss of arterial-phase hypervascularity on real-time contrast-enhanced harmonic sonography at low acoustic energy. J Clin Ultrasound 2003;31:387-391.
99. Piscaglia F, Corradi F, Mancini M, Giangregorio F, Tamberi S, Ugolini G, Cola B, et al. Real time contrast enhanced ultrasonography in detection of liver metastases from gastrointestinal cancer. BMC Cancer 2007;7:171.
100. Venturi A, Piscaglia F, Silvagni E, Righini R, Fabbrizio B, Cescon M, Bolondi L. Role of real-time contrast-enhanced ultrasound in the assessment of metastatic portal vein thrombosis. Ultraschall Med 2007;28:75-78.
101. Piscaglia F, Gianstefani A, Ravaioli M, Golfieri R, Cappelli A, Giampalma E, Sagrini E, et al. Criteria for diagnosing benign portal vein thrombosis in the assessment of patients with cirrhosis and hepatocellular carcinoma for liver transplantation. Liver Transpl 2010;16:658-667.
102. Bondini S, Leoni S, Bolondi L. Squamous cell carcinoma of the liver: metastasis or primary neoplasm? J Clin Ultrasound 2005;33:477-478.
103. Bolondi L, Correas JM, Lencioni R, Weskott HP, Piscaglia F. New perspectives for the use of contrast-enhanced liver ultrasound in clinical practice. Dig Liver Dis 2007;39:187-195.
104. Celli N, Gaiani S, Piscaglia F, Zironi G, Camaggi V, Leoni S, Righini R, et al. Characterization of liver lesions by real-time contrast-enhanced ultrasonography. Eur J Gastroenterol Hepatol 2007;19:3-14.
105. Venturi A, Piscaglia F, Vidili G, Flori S, Righini R, Golfieri R, Bolondi L. Diagnosis and management of hepatic focal nodular hyperplasia. J Ultrasound 2007;10:116-127.
106. Ignee A, Livraghi T, Tranquart F, Bolondi L, Dietrich CF, Albrecht T. Verbesserte Detektion von Leberläsionen durch Ultraschall-Kontrastmittel der zweiten Generation im Vergleich zur konventionellen Sonographie. Endoskopie heute 2009;22:105-109.
107. Piscaglia F, Lencioni R, Sagrini E, Pina CD, Cioni D, Vidili G, Bolondi L. Characterization of focal liver lesions with contrast-enhanced ultrasound. Ultrasound Med Biol 2010;36:531-550.
108. Piscaglia F, Venturi A, Mancini M, Giangregorio F, Vidili G, Magnolfi F, Mirarchi M, et al. Diagnostic features of real-time contrast-enhanced ultrasound in focal nodular hyperplasia of the liver. Ultraschall Med 2010;31:276-282.
109. Salvatore V, Bolondi L. Clinical impact of ultrasound-related techniques on the diagnosis of focal liver lesions. Liver Cancer 2012;1:238-246.
110. Bolondi L. The appropriate allocation of CEUS in the diagnostic algorithm of liver lesions: a debated issue. Ultrasound Med Biol 2013;39:183-185.
111. Galassi M, Iavarone M, Rossi S, Bota S, Vavassori S, Rosa L, Leoni S, et al. Patterns of appearance and risk of misdiagnosis of intrahepatic cholangiocarcinoma in cirrhosis at contrast enhanced ultrasound. Liver Int 2013;33:771-779.
112. Iavarone M, Piscaglia F, Vavassori S, Galassi M, Sangiovanni A, Venerandi L, Forzenigo LV, et al. Contrast enhanced CT-scan to diagnose intrahepatic cholangiocarcinoma in patients with cirrhosis. J Hepatol 2013;58:1188-1193.

113. Leoni S, Piscaglia F, Granito A, Borghi A, Galassi M, Marinelli S, Terzi E, et al. Characterization of primary and recurrent nodules in liver cirrhosis using contrast-enhanced ultrasound: which vascular criteria should be adopted? Ultraschall Med 2013;34:280-287.
114. Pallotti MC, Nannini M, Agostinelli C, Leoni S, Scioscio VD, Mandrioli A, Lolli C, et al. Long-term durable response to lenalidomide in a patient with hepatic epithelioid hemangioendothelioma. World J Gastroenterol 2014;20:7049-7054.
115. Leoni S, Serio I, Pecorelli A, Marinelli S, Bolondi L. Contrast-enhanced ultrasound in liver cancer. Hepat Oncol 2015;2:51-62.
116. Piscaglia F, Iavarone M, Galassi M, Vavassori S, Renzulli M, Forzenigo LV, Granito A, et al. Cholangiocarcinoma in Cirrhosis: Value of Hepatocyte Specific Magnetic Resonance Imaging. Dig Dis 2015;33:735-744.
117. Renzulli M, Biselli M, Brocchi S, Granito A, Vasuri F, Tovoli F, Sessagesimi E, et al. New hallmark of hepatocellular carcinoma, early hepatocellular carcinoma and high-grade dysplastic nodules on Gd-EOB-DTPA MRI in patients with cirrhosis: a new diagnostic algorithm. Gut 2018;67:1674-1682.
118. Salvatore V, Borghi A, Sagrini E, Galassi M, Gianstefani A, Bolondi L, Piscaglia F. Quantification of enhancement of focal liver lesions during contrast-enhanced ultrasound (CEUS). Analysis of ten selected frames is more simple but as reliable as the analysis of the entire loop for most parameters. Eur J Radiol 2012;81:709-713.
119. Foschi FG, Piscaglia F, Pompili M, Corbelli C, Marano G, Righini R, Alvisi V, et al. Real-time contrast-enhanced ultrasound--a new simple tool for detection of peritoneal-pleural communications in hepatic hydrothorax. Ultraschall Med 2008;29:538-542.
120. Piscaglia F, Gualandi S, Galassi M, Giampalma E, Golfieri R, Bolondi L. Contrast enhanced ultrasonography for the evaluation of coil embolization of splenic artery aneurysm. Circulation 2010;122:e451-454.
121. Piscaglia F, Bolondi L, Italian Society for Ultrasound in M, Biology Study Group on Ultrasound Contrast A. The safety of Sonovue in abdominal applications: retrospective analysis of 23188 investigations. Ultrasound Med Biol 2006;32:1369-1375.
122. Albrecht T, Blomley M, Bolondi L, Claudon M, Correas JM, Cosgrove D, Greiner L, et al. Guidelines for the use of contrast agents in ultrasound. January 2004. Ultraschall Med 2004;25:249-256.
123. Italian Association for the Study of the L, Panel AE, Committee AC, Bolondi L, Cillo U, Colombo M, Craxi A, et al. Position paper of the Italian Association for the Study of the Liver (AISF): the multidisciplinary clinical approach to hepatocellular carcinoma. Dig Liver Dis 2013;45:712-723.
124. Bota S, Piscaglia F, Marinelli S, Pecorelli A, Terzi E, Bolondi L. Comparison of international guidelines for noninvasive diagnosis of hepatocellular carcinoma. Liver Cancer 2012;1:190-200.
125. Claudon M, Cosgrove D, Albrecht T, Bolondi L, Bosio M, Calliada F, Correas JM, et al. Guidelines and good clinical practice recommendations for contrast enhanced ultrasound (CEUS) - update 2008. Ultraschall Med 2008;29:28-44.
126. Llovet JM, Ricci S, Mazzaferro V, Hilgard P, Gane E, Blanc JF, de Oliveira AC, et al. Sorafenib in advanced hepatocellular carcinoma. N Engl J Med 2008;359:378-390.
127. Brandi G, de Rosa F, Bolondi L, Agostini V, Di Girolamo S, Nobili E, Biasco G. Durable complete response of hepatocellular carcinoma after metronomic capecitabine. Tumori 2010;96:1028-1030.
128. Salvatore V, Baron Toaldo M, Marinelli S, Milazzo M, Palama C, Venerandi L, Cipone M, et al. Early prediction of treatment response to sorafenib with elastosonography in a mice

xenograft model of hepatocellular carcinoma: a proof-of-concept study. Ultraschall Med 2013;34:541-549.
129. Golfieri R, Giampalma E, Renzulli M, Cioni R, Bargellini I, Bartolozzi C, Breatta AD, et al. Randomised controlled trial of doxorubicin-eluting beads vs conventional chemoembolisation for hepatocellular carcinoma. Br J Cancer 2014;111:255-264.
130. Leoni S, Piscaglia F, Serio I, Terzi E, Pettinari I, Croci L, Marinelli S, et al. Adherence to AASLD guidelines for the treatment of hepatocellular carcinoma in clinical practice: experience of the Bologna Liver Oncology Group. Dig Liver Dis 2014;46:549-555.
131. Marinelli S, Salvatore V, Baron Toaldo M, Milazzo M, Croci L, Venerandi L, Pecorelli A, et al. Evaluation of the impact of transient interruption of antiangiogenic treatment using ultrasound-based techniques in a murine model of hepatocellular carcinoma. BMC Cancer 2014;14:403.
132. Baron Toaldo M, Salvatore V, Marinelli S, Palama C, Milazzo M, Croci L, Venerandi L, et al. Use of VEGFR-2 targeted ultrasound contrast agent for the early evaluation of response to sorafenib in a mouse model of hepatocellular carcinoma. Mol Imaging Biol 2015;17:29-37.
133. Golfieri R, Mosconi C, Cappelli A, Giampalma E, Galaverni MC, Pettinato C, Renzulli M, et al. Efficacy of radioembolization according to tumor morphology and portal vein thrombosis in intermediate-advanced hepatocellular carcinoma. Future Oncol 2015;11:3133-3142.
134. Camaggi V, Piscaglia F, Bolondi L. Recent advances in the imaging of hepatocellular carcinoma. From ultrasound to positron emission tomography scan. Saudi Med J 2007;28:1007-1014.
135. Bolondi L, Burroughs A, Dufour JF, Galle PR, Mazzaferro V, Piscaglia F, Raoul JL, et al. Heterogeneity of patients with intermediate (BCLC B) Hepatocellular Carcinoma: proposal for a subclassification to facilitate treatment decisions. Semin Liver Dis 2012;32:348-359.
136. Fontana G, Caletti G, Bolondi L, Costa P. [Recent acquisitions on the etiopathogenesis of Whipple's disease. Report of a case with isolation of Klebsiella pneumoniae from the intestinal mucosa]. Recenti Prog Med 1974;56:322-357.
137. Fontana G, Bolondi L, Plicchi G, Conti M, Gullo L, Caletti GC, Costa P. [Pancreatic echotomography : use, value and limits in the diagnosis of chronic pancreatitis]. Recenti Prog Med 1975;59:123-137.
138. Fontana G, Gullo L, Ventrucci M, Costa PL, Caletti GC, Bolondi L, Ripani R. [Criteria and trends in medical therapy in chronic pancreatitis]. Minerva Med 1977;68:2103-2108.
139. Gullo L, Bolondi L, Fontana G, Tessari R, Costa PL, Caletti GC, Miglioli M, et al. [Ascites in chronic pancreatitides. Report of 2 cases]. Minerva Med 1977;68:3169-3175.
140. Gullo L, Fontana G, Costa PL, Bolondi L, Ventrucci M, Caletti GC, Ripani R, et al. [Etiopathogenetic aspects of chronic pancreatitis]. Minerva Med 1977;68:2057-2061.
141. Ventrucci M, Gullo L, Capelli M, Plate L, Bolondi L, Fontana G. [Combined stimulation of the beta cells in chronic pancreatitis]. Recenti Prog Med 1979;66:71-76.
142. Caletti G, Brocchi E, Agostini D, Balduzzi A, Bolondi L, Labo G. Sensitivity of endoscopic retrograde pancreatography in chronic pancreatitis. Br J Surg 1982;69:507-509.
143. Bolondi L, Priori P, Gullo L, Santi V, Li Bassi S, Barbara L, Labo G. Relationship between morphological changes detected by ultrasonography and pancreatic exocrine function in chronic pancreatitis. Pancreas 1987;2:222-229.
144. Bolondi L, Li Bassi S, Gaiani S, Barbara L. Sonography of chronic pancreatitis. Radiol Clin North Am 1989;27:815-833.

145. Bolondi L, Li Bassi S, Gaiani S, Santi V, Gullo L, Barbara L. Impaired response of main pancreatic duct to secretin stimulation in early chronic pancreatitis. Dig Dis Sci 1989;34:834-840.
146. Ventrucci M, Bolondi L, Caletti GC, Fontana G. [Therapeutic effect of a pharmacologic combination of choleretics and digestive enzymes in exocrine pancreatic insufficiency]. Minerva Med 1975;66:819-823.
147. Bolondi L, Li Bassi S, Gaiani S, Campione O, Marrano D, Barbara L. Diagnosis of islet cell tumor by means of endoscopic ultrasonography. J Clin Gastroenterol 1990;12:218-221.
148. Salvatore V, Vidili G, Sagrini E, Borghi A, Bolondi L. Contrast-enhanced ultrasonography features of extramedullary hematopoiesis presenting as a presacral mass: an update of the literature. Ultraschall Med 2010;31:413-415.
149. Bolondi L, Gaiani S, Casanova P, Testa S, Priori P, Labo G. Improvement of pancreatic ultrasound imaging after secretin administration. Ultrasound Med Biol 1983;9:497-501.
150. Bolondi L, Gaiani S, Gullo L, Labo G. Secretin administration induces a dilatation of main pancreatic duct. Dig Dis Sci 1984;29:802-808.
151. Bolondi L, Caletti GC, Gandolfi L, Rossi A, Solmi L, Fontana G, Labo G. Ultrasonography in the diagnosis of cholestatic jaundice. Comparison with endoscopic retrograde cholangio-pancreatography. Acta Gastroenterol Belg 1978;41:615-622.
152. Caletti GC, Verucchi G, Vitolo A, Brocchi E, Bolondi L, Labo G. [Endoscopic treatment of obstructive cholangitis]. Minerva Chir 1980;35:559-563.
153. Caletti GC, Vandelli A, Bolondi L, Fontana G, Labo G. Endoscopic retrograde cholangiography (ERC) through artificial endoscopic choledocho-duodenal fistula. Endoscopy 1978;10:203-206.
154. Caletti GC, Verucchi G, Bolondi L, Labo G. Diathermy ERCP: an alternative method for endoscopic retrograde cholangiopancreatography (ERCP) in jaundiced patients. Gastrointest Endosc 1980;26:13-15.
155. Bolondi L, Casiglio P, Gaiani S, Labriola E. [Renal angiomyolipoma. Analysis of a clinical case in the light of current diagnostic possibilities]. Minerva Med 1984;75:173-176.
156. Donati G, Piscaglia F, Coli L, Silvagni E, Righini R, Donati G, Pini P, et al. Acute systemic, splanchnic and renal haemodynamic changes induced by molecular adsorbent recirculating system (MARS) treatment in patients with end-stage cirrhosis. Aliment Pharmacol Ther 2007;26:717-726.
157. Gullo L, Bolondi L, Priori P, Casanova P, Labo G. Inhibitory effect of atropine on cholecystokinin-induced gallbladder contraction in man. Digestion 1984;29:209-213.
158. Gullo L, Bolondi L, Scarpignato C, Priori P, Casanova P, Labo G. Effect of somatostatin and thyrotropin-releasing hormone on cholecystokinin-induced gallbladder emptying. Dig Dis Sci 1986;31:1345-1350.
159. Gullo L, Ancona D, Pezzilli R, Fusconi F, Bolondi L. Study of the effect of neurotensin on meal- and cerulein-induced gallbladder contraction. Digestion 1992;53:67-71.
160. Bolondi L, Gaiani S, Testa S, Labo G. Gall bladder sludge formation during prolonged fasting after gastrointestinal tract surgery. Gut 1985;26:734-738.
161. Gaiani S, Serra C, Cervellera M, Campione O, Bolondi L, Miglioli M. Gallstone ileus in Caroli's disease. Am J Gastroenterol 2000;95:3642-3643.
162. Sagrini E, Pecorelli A, Pettinari I, Cucchetti A, Stefanini F, Bolondi L, Piscaglia F. Contrast-enhanced ultrasonography to diagnose complicated acute cholecystitis. Intern Emerg Med 2016;11:19-30.

163. Bolondi L, Gaiani S, Brignola C, Campieri M, Rigamonti A, Zironi G, Gionchetti P, et al. Changes in splanchnic hemodynamics in inflammatory bowel disease. Non-invasive assessment by Doppler ultrasound flowmetry. Scand J Gastroenterol 1992;27:501-507.
164. Bolondi L, Li Bassi S, Gaiani S, Zironi G, Paparo GF, Barbara L. Changes in mesenteric venous flow due to celiac sprue. Dig Dis Sci 1992;37:925-928.
165. Casali A, Gaiani S, Piscaglia F, Gramantieri L, Masi L, Valgimigli M, Bolondi L. A case of extracranial vertebral artery dissection with spontaneous recovery Diagnosis and follow-up by duplex and color Doppler. Eur J Ultrasound 1997;6:197-201.
166. Sofia S, Casali A, Bolondi L. Sonographic findings in abdominal hereditary angioedema. J Clin Ultrasound 1999;27:537-540.
167. Sofia S, Casali A, Bolondi L. Sonographic diagnosis of adult intussusception. Abdom Imaging 2001;26:483-486.
168. Corradi F, Piscaglia F, Flori S, D'Errico-Grigioni A, Vasuri F, Tame MR, Andreone P, et al. Assessment of liver fibrosis in transplant recipients with recurrent HCV infection: usefulness of transient elastography. Dig Liver Dis 2009;41:217-225.
169. Gianstefani A, Salvatore V, Crespi C, Bolondi L. Stiffness and amyloidosis: to be continued. Eur J Gastroenterol Hepatol 2010;22:1507.
170. Lanzi A, Gianstefani A, Mirarchi MG, Pini P, Conti F, Bolondi L. Liver AL amyloidosis as a possible cause of high liver stiffness values. Eur J Gastroenterol Hepatol 2010;22:895-897.
171. Piscaglia F, Salvatore V, Di Donato R, D'Onofrio M, Gualandi S, Gallotti A, Peri E, et al. Accuracy of VirtualTouch Acoustic Radiation Force Impulse (ARFI) imaging for the diagnosis of cirrhosis during liver ultrasonography. Ultraschall Med 2011;32:167-175.
172. Salvatore V, Borghi A, Peri E, Colecchia A, Li Bassi S, Montrone L, Di Donato R, et al. Relationship between hepatic haemodynamics assessed by Doppler ultrasound and liver stiffness. Dig Liver Dis 2012;44:154-159.
173. Piscaglia F, Salvatore V, Mulazzani L, Cantisani V, Colecchia A, Di Donato R, Felicani C, et al. Differences in liver stiffness values obtained with new ultrasound elastography machines and Fibroscan: A comparative study. Dig Liver Dis 2017;49:802-808.
174. Piscaglia F, Salvatore V, Mulazzani L, Cantisani V, Colecchia A, Di Donato R, Felicani C, et al. Corrigendum to "Differences in liver stiffness values obtained with new ultrasound elastography machines and fibroscan: A comparative study" [Dig. Liver Dis. 49 (2017) 802-808]. Dig Liver Dis 2018;50:633.
175. Piscaglia F, Tewelde AG, Righini R, Gianstefani A, Calliada F, Bolondi L. Knowledge of the bio-effects of ultrasound among physicians performing clinical ultrasonography: Results of a survey conducted by the Italian Society for Ultrasound in Medicine and Biology (SIUMB). J Ultrasound 2009;12:6-11.
176. Gozzetti G, Mazziotti A, Bolondi L, Cavallari A, Grigioni W, Casanova P, Bellusci R, et al. Intraoperative ultrasonography in surgery for liver tumors. Surgery 1986;99:523-530.
177. Gozzetti G, Mazziotti A, Cavallari A, Bellusci R, Bolondi L, Grigioni W, Bragaglia R, et al. Clinical experience with hepatic resections for hepatocellular carcinoma in patients with cirrhosis. Surg Gynecol Obstet 1988;166:503-510.
178. Gandolfi L, Mazziotti A, Caletti GC, Bolondi L, Gozzetti G. The role of gastroenterologists and digestive surgeons in ultrasonography. Ital J Gastroenterol 1992;24:225-229.