



EFSUMB History of Ultrasound

Editor: Christoph F. Dietrich

Norway, Gastroenterology

Svein Ødegaard¹

Corresponding author and affiliation

Svein Ødegaard, MD, Dr.med., Internal Medicine and Gastroenterology, Professor emeritus, former Director, Department of Medicine and Founder and Director of Norwegian National Centre for Ultrasound in Gastroenterology, Haukeland University Hospital and University of Bergen, Bergen, Norway

Acknowledgment: I want to thank all my teachers, coworkers, students and friends for a fantastic ultrasound journey and friendship.

Introduction

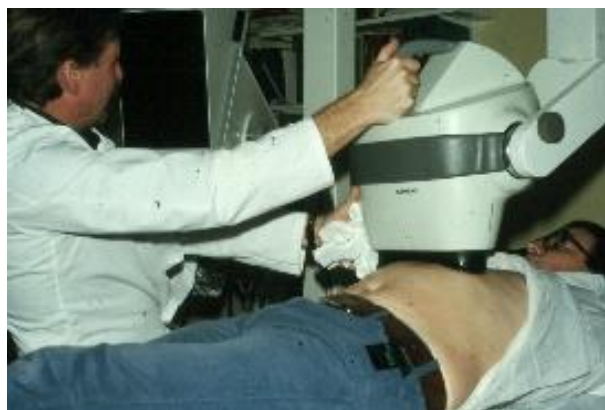Ultrasound (US) examination of abdominal organs in Norway was initiated in the mid-1970-ties by enthusiasts from various specialties, particularly radiology and internal medicine. However, before and in the beginning of the real-time era the interest in ultrasound among Norwegian gastroenterologists was limited, and the method was mainly used for imaging of larger abdominal organs.

The Norwegian Gastroenterological Association established a working group in GI-ultrasound already in the 90-ties, but despite the effort to stimulate gastroenterologists to include ultrasound in their daily work, this was a slow and heavy task. Nevertheless, in the last two decades (2019) many younger gastroenterologists have discovered the value of ultrasound due to smaller (pocket sized) and cheaper instruments.

Pioneers

Gastroenterologists at Haukeland University Hospital in Bergen realized already in 1976 that US could be helpful in imaging abdominal organs. At that time the internist Ole Martin Pedersen, Department of clinical physiology, had access to an ultrasound compound scanner, and the first still US images were acquired in our hospital. However, real-time US was at that time already available in some countries, and some gastroenterologists used US as a supplement to endoscopy in their daily work. After a three-years training programme in Germany (1977-1980, Svein Ödegaard), US was integrated in the Gastrolab in Bergen in 1981.

Figure 1 US-training in Bietigheim, Germany 1978 with a Siemens Vidoson real-time scanner. The large transducer is filled with water and contains rotating 2.4 MHz transducers.

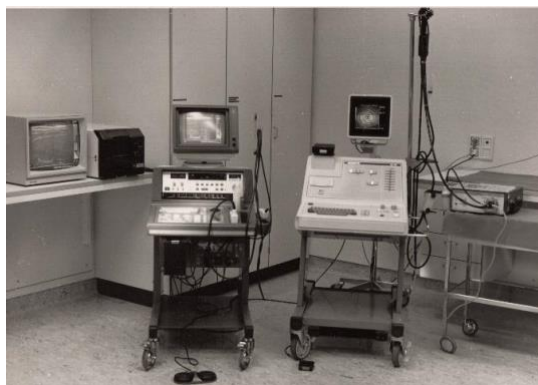


Because US does not harm the patient it was also possible to obtain repeated og long real-time movie sequences to study gastrointestinal (patho)physiology e.g. gastric emptying and intestinal motility. Thus, in the 80-ties a GI-ultrasound group was established by Ole Martin Pedersen, Bjarte Børkje, Christen Bang, Trygve Hausken and Svein Ödegaard. Ultrasound became soon an important diagnostic tool in daily clinical work and GI-research, and Trygve Hausken developed new examination techniques to study gut motility.

The group was also scientifically supported by an experienced colleague in GI-research, Arnold Berstad from 1987. In the 90-ties the group was strengthened by Odd Helge Gilja (later EFSUMB-president) who was very dedicated to GI-ultrasound. He contributed in the following years significantly in developing new US-methods and heading scientific projects.

A few GI-surgeons found ultrasound of interest, but Inge Glambek (current president of The Norwegian Surgical Association – 2019), the late Arild Olsen in Stavanger and Ronald Mårvik in Trondheim were pioneers in abdominal-, rectal-, peroperativ and laparoscopic ultrasound. They arranged education courses and lectures already in the 80-ties to stimulate also GI-surgeons to include ultrasound in their work.

Figure 2 GI-Ultrasound lab in Bergen 1988 with a Siemens Sonoline scanner (left) and Olympus echoendoscope (right).



Technology

Transcutaneous ultrasound

Ultrasound was long considered less suitable to study the GI-tract itself due to low image resolution and disturbances from intraluminal content. Improved US technology and high frequency transducers made it possible to visualize the GI-wall and the individual wall layers, especially if fluid was inserted into the GI-tract. Trygve Hausken showed already in 1986 that a meat soup was a good medium to image and study stomach and duodenum motility. He was also the first to utilize Doppler technology for this purpose, which for a long time was regarded difficult to use in the abdominal area. In the late 80-ties Doppler was combined with B-imaging (Duplex) and proved helpful in visualization and hemodynamic examination of both larger and smaller veins and arteries. Hausken was also the first to demonstrate Duplex-scanning (later also including colour Doppler) to study transpyloric flow of a meat soup in the stomach. In the years to come Duplex-scanning became normal in GI-ultrasound examinations.

Figure 3 Gastrointestinal motility ultrasound (Hausken, PhD 1992). Gastric emptying and transpyloric flow of a meat soup using B-mode and colour Doppler.

a

FUNCTIONAL DYSPEPSIA - ANTRAL MOTILITY AND
SYMPTOMS IN RESPONSE TO STRESS AND
MEDICAL INTERVENTION

by

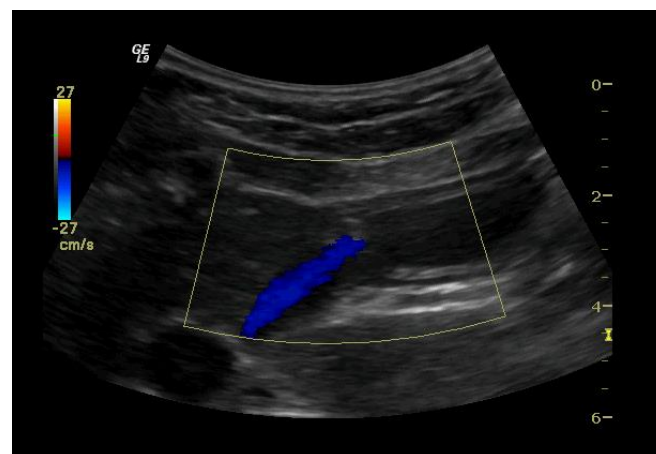
TRYGVE HAUSKEN



Division of Gastroenterology
Medical Department A
University of Bergen

Bergen, Norway 1992

b



Furthermore, Hauskens work within 3D-imaging of the stomach was a valuable contribution to volume estimation of hollow organs. His important work lead to a number of high quality publications which later became a prerequisite for other studies and PhD degrees.

In the 90-ties Odd Helge Gilja developed additional new methods to examine the stomach and other abdominal organs. He was also the first who defined a method to examine the stomach's upper part and eventually the whole stomach, both with 2D and 3D ultrasound. He also compared ultrasound with other imaging methods e.g. MRI in this context.


Figure 4 2D and 3D ultrasound for studying gastric motility (Gilja, Phd 1997) (a). The image shows antral contraction reconstructed in 3D. Prize Winner Trygve

Hausken (b), “The Ultrasound in Medicine and Biology Clinical Prize 1998” for the paper “Estimation of the human liver volume and configuration using three-dimensional ultrasonography”.

a


**Functional Dyspepsia
Studied by Two- and Three-
Dimensional Ultrasonography**
Significance of Gastric Meal Accommodation

Odd Helge Gilja



Medical Department A
University of Bergen
Bergen, Norway 1997

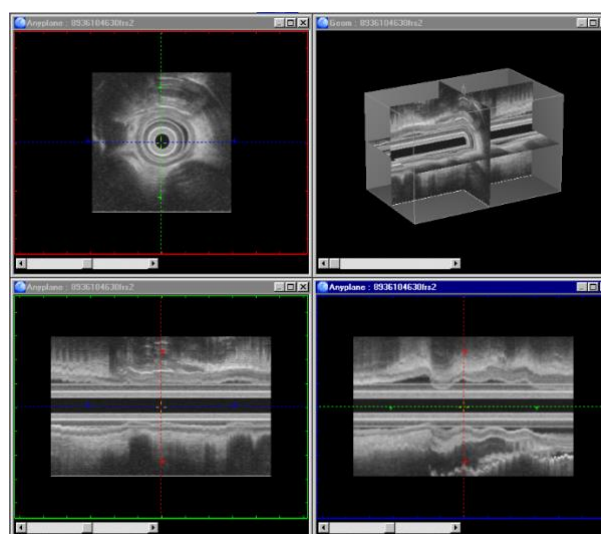
b



The collaboration with Norwegian and international equipment producers, software experts and engineers (Vingmed, Toshiba, Siemens, Olympus, Fujinon, Pentax, Christian Michelsen Research (CMR), SINTEF e.g). was crucial for making progress within both clinical and scientific ultrasound work. In Norway, Vingmed (located in Horten, Norway) was a successful and innovative company which developed ultrasound machines, in the beginning mainly used in cardiology. Some

gastroenterologists became part of Vingmed research group, and together with Christian Michelsen Research (CMR) and University of Bergen an ultrasound professorship (S. Ödegaard) was established. The GI-group in Bergen (Trygve Hausken, Knut Matre, Odd Helge Gilja, Lars Birger Nesje) did in this context for years important ultrasound work also within the field of 3D-US. The group became also involved in the development of ultrasound miniprobes together with professor Michael B. Kimmey, Fred E. Silverstein, Roy W. Martin (University of Washington, Seattle) and later in the commercialization (Fujinon, Japan). Collaboration with Olympus was mainly based on improving images obtained with both dedicated echoendoscopes and miniature US-probes. The first 3D-EUS images with these transducers were, to our knowledge, published by our group using algorithms developed by CMR. Thus, postprocessing with anyplane slicing of 3D data sets could be performed for detailed examination of e.g. tumor ingrowth (staging) in the GI-wall.

Figure 5 3D display (EchoPac 3D software) of oesophagus based on images acquired during pull-back of a radial-scanning ultrasound probe.




Interventional ultrasound (ultrasound-guided intervention)

Ultrasound was early found to be very helpful by some gastroenterologist as a “semiguided” tool in performing interventional procedures e.g. liver biopsy. Obtaining “blind” liver biopsies was the normal procedure, but US could help secure the puncture route. When new dedicated biopsy

transducers for precisely guiding interventions became available a new era started. In parenchymal liver diseases US could demonstrate focal lesions and tissue irregularities which was crucial in obtaining reliable cytology and biopsies with less hazard to the patient. Thus, tissue of the area of interest could better be identified.

Interventional EUS in Norway started in the 90-ties using the Pentax linear EUS-system. We realized that EUS-interventions should only be performed by an experienced endoscopist with considerable experience in both endoscopy and understanding US-images. Sometimes it was difficult to define and separate echopoor structures from vessels. If this was mistaken it could have serious complications. When EUS spectral and colour Doppler became available this increased the safety considerably.

Figure 6 **Linear transducer for guiding fine-needle aspiration cytology.**



Endoscopic ultrasound

Endoscopic ultrasound (EUS) in Norway was initiated by Svein Ödegaard and Bjarte Børkje in 1987, and Haukeland Hospital was among the first hospitals in Europe to offer this procedure using both dedicated echoendoscopes and miniprobos. Our combined experience in GI-endoscopy and external ultrasound was very helpful in performing reliable examinations from the very beginning. As mentioned our work was initially concentrated on understanding US-images aquired with high frequency US-probes from the inside of the body.

The first EUS-education programmes in Norway in the early 90-ties were sparely visited, but today (2019) they are fully booked. In the 90-ties and later, Lars Birger Nesje, Bergen and Knut Johnsen, Tromsø became leading EUS-experts, and Nesje defended his PhD in EUS of the upper GI-tract in 2001. He was also the first performing EUS-guided invasive procedures in Norway.

Figure 7 The first international EUS meeting in Scandinavia (1987) and first EUS- PhD (Lars B. Nesje, 2001) in Norway.

a

PROGRAM

WORKSHOP ON ENDOSCOPIC ULTRASONOGRAPHY

SCANDIC HOTELL 24. APRIL 1987, BERGEN

Organizing committee: C J Bang, B Børkje, L Digraanes and S Ødegaard, Med. Dept. Section of Gastroenterology, Haukeland University Hospital, Bergen in cooperation with Smith Kline & French, James Polack Norway A/S and Brüel & Kjør, Norway.

Languages: Norwegian and English.

FRIDAY 24. APRIL

10.30 - 10.40 Opening (S Ødegaard, Bergen).

10.40 - 11.15 Moderator: B Børkje, Bergen
Ultrasound (K. Matre, Bergen).

11.15 - 11.30 Ultrasonography in gastroenterology (S. Ødegaard).

11.30 - 11.50 Endoscopy of the upper GI-tract. (M. Osnes, Oslo).

11.50 - 12.30 Abdominal Ultrasonography in G.I. diseases. (H. Lutz, Bayreuth and Erlangen).

12.30 - 13.45 L U N C H

13.45 - 14.30 Moderator: S. Ødegaard.
Endoscopic Ultrasonography in Germany. (H. Lutz).

14.30 - 14.45 Discussion

14.45 - 15.30 Endoscopic Ultrasonography of the upper GI-tract. (T. Lok Tio, Amsterdam).


15.30 - 16.00 Endoscopic Ultrasonography of the rectum. (T. Lok Tio, Amsterdam).

16.05 - 16.40 Endoscopic Ultrasonography of the rectum. (J Beynon, Bristol).

16.45 - 17.00 Discussion. EUS in Norway ?

END OF WORKSHOP

b



Education, events and congresses

Education for gastroenterologists and medical students

Some gastroenterologists and internists suggested already in the 70-ties that abdominal US also should be performed by them. There were several reasons for this, US was a safe and time saving method which could help the clinician bedside both in hospitals and outpatient clinic. Furthermore, US was already a common clinical method in the hands of gynecologists, cardiologists e.g. Thus, a discussion started in Norway with the title “Ultrasound for everybody”?, (Ödegaard, Norw J Medicine, 1980), and training courses in GI-ultrasound for medical doctors, technicians e.g. soon started on a regular basis (Pedersen and Ödegaard). To stimulate young physicians to get an early relationship to ultrasound, we offered medical students in Bergen already in 1994 compulsory ultrasound education. This became a successful story and US is today included in the basic education at several Norwegian universities. The development of pocket sized transducers has led to “Point of care US”, and medical students and young doctors regard today US as a normal clinical tool.

Figure 8 **Ultrasound demonstrated at the “University of Bergen Research Days” for young people by Kim Nylund.**



Events and congresses

Due to limited interest in US among Norwegian gastroenterologists for many years it was difficult to arrange events and congresses in Norway. However, GI-ultrasound was presented at national ultrasound-, surgery- and gastroenterology meetings. Furthermore, some Norwegian gastroenterologists were invited speakers at international events and congresses and/or as presenters of scientific papers and posters. After 2000, some international US/EUS meetings have been arranged in Norway and in 2020 Euroson will take place in Bergen.

Figure 9 **Kirkenes, Norway 1998. The Norwegian-Russian Barents Sea meeting with Euroson School, supported by the Norwegian Government.**



International collaboration

International contact with colleagues working within GI-ultrasound was important. The Norwegian Society for Diagnostic Ultrasound was established already in 1977, but at that time mainly radiologists, gynecologists and cardiologists took part. Svein Ödegaard established contact with ultrasound experts in Germany (Gerhard Rettenmaier, Karlheinz Seitz, Harald Lutz and Dieter Busch) and USA (The Bergen-Seattle Research Exchange Programme, Roy W. Martin, Michael B. Kimmey and Fred E. Silverstein, Seattle) and a close cooperation lasted for many years. After that the international collaboration has extended to include colleagues and groups in many countries.

In 1998 EFSUMB (president Luigi Bolondi), The Norwegian Ultrasound Society and The Norwegian Ministry of Foreign affairs (The Norwegian-Russian Barents Sea collaboration) arranged a successful Euroson course in Kirkenes, Norway for Russian and Norwegian colleagues. Furthermore, several gastroenterologists have so far (2019) been leaders, members and officers in national and international ultrasound societies and organizations e.g. Odd Helge Gilja, EFSUMB-president and WFUMB committee education leader, Svein Ødegaard, EU-Research council evaluator, honorary member DEGUM, senior member AIUM, EFSUMB board member and fellow).

New applications of ultrasound in gastroenterology


The historic journey through US in gastroenterology in Norway has shown how the work through many years has formed the basis for the development of new methods and technology up til now (2019). Novel transabdominal and intraluminal highfrequency ultrasound techniques can give detailed images of GI organs. Thus, pathology can be detected at an early stage and follow-up during treatment is possible using a patient-friendly method. US-guided intervention (e.g. biopsy, endomucosal resection), biomechanics and motility, 3D ultrasound, contrast-enhanced ultrasound, SRI, sonoelastography, molecular imaging and nanotechnology are some improved and new techniques with promising future in the diagnosis and treatment of digestive diseases. These methods are today included in clinical and project related US work in Norwegian gastroenterology.

Norwegian National Centre for ultrasound in Gastroenterology


was established in Bergen in 2001. The centre was located at Department of Medicine, Haukeland University Hospital (Director Svein Ödegaard) and today (2019) the centre has about 20 (part time) employees, phd students etc. (Director Odd Helge Gilja). National and international GI-ultrasound courses, education programmes, scientific collaboration within imaging, software development, technical improvement e.g. are some of the functions of the centre.

Figure 10 These books are available for our education programmes.

a



b



Conclusion

If you believe in something, go for it! In medicine doctors have always searched for methods to make a correct diagnosis and to find the best treatment for a patient. Furthermore, an important goal is also to minimize the risk and prevent harmful events and pain. Based on pioneers work within medicine, technology, imaging and information technology, ultrasound in medicine is today a practical, relatively cheap and safe method for both diagnostics and treatment. The clinician has got a tool which is regarded as an extension of the hand and eye. Furthermore, understanding US is a prerequisite for gastroenterologists performing the combination of ultrasound and endoscopy (endoscopic ultrasound-EUS), a technique which today has replaced more diagnostic and therapeutic procedures.

“Historic” References

- [Odegaard S. Rapid ultrasonic diagnostic in acute abdominal diseases. J Norwegian Med Ass. 1981, 32: 1831-4.
- Odegaard S, Vetvik K, Børkje B, Schrumph E, Bakkevold, K, Pedersen OM, Kråkenes J. Ultrasound examination and ERCP in patients with biliary diseases. J Norwegian Med Ass. 1984, 104: 1315-7.
- Odegaard S, Kimmey MB, Børkje B, Hausken T. Endoscopic ultrasonographic findings in

benign and malignant diseases of the stomach. Eur J Radiol 1990, 11,3,175-179

- Hausken T, Ødegaard S, Berstad A. Antroduodenal motility studied by real-time ultrasonography. Effect of enprostil. Gastroenterology 1991,1,59-63
- Odegaard S, Matre K, Kimmey MB. Transendoskopische Ultrasonographie des oberen Gastrointestinaltractus bei der routine Endoskopie. Ultraschall in Klin & Prax, 1992,7,99-103.
- Hausken T, Odegaard S, Berstad A. Antroduodenal motility and movements of luminal content studied by Duplex-sonography. Gastroenterology 1992, 102,1583 - 1590.
- Odegaard S, Kimmey MB, Martin RW, Cheung AHS, Yee,HC, Jiranek GC, Silverstein FE. The effects of applied pressure on the thickness, layers and echogenicity of gastrointestinal wall ultrasound images. Gastrointest Endosc 1992,38,351-356
- Odegaard S, Kimmey MB. Location of the muscularis mucosae on high frequency gastrointestinal ultrasound images. Eur J Ultrasound 1994, 1, 39-50.
- Nesje LB., Odegaard S., Kimmey MB. Transendoscopic ultrasonography during coventional upper gastrointestinal endoscopy. Clinical evaluation of a linear 20 MHz probe system. Scand J Gastroenterol 1997, 32:500-508.
- Odegaard S, Kimmey MB, Cheung AHS, Nesje LB, Morild I, Silverstein FE, Martin RW.High frequency endosonography of gastrointestinal arteries. Potential and limitations defined in vitro. Eur J Ultrasound,1995, 313-319.
- Gilja OH, Thune N, Matre K, Hausken T, Berstad A, Odegaard S. In vitro evaluation of three dimensional ultrasonography in volume estimation of organs. Ultrasound Med & Biol, 1994, 20,157-165.
- Hausken T, Thune N, Matre K, Gilja OH, Odegaard S, Berstad A. Volume estimation of the gastric antrum and the gallbladder in patients with functional dyspepsia and erosive prepyloric changes, using 3D ultrasonography. Neurogastroenterol. Mot. 1994, 6,263-270.
- Kimmey MB & Odegaard S. High resolution endoluminal sonography of the upper gastrointestinal tract: the linear scanning ultrasound probe. In: GASTROINTESTINAL ENDOSONOGRAPHY (Eds. van Dam J & Sivak M), W.B. Saunders 1998.
- Sivak M, Yasuda, Røsch T, Odegaard S, Lok Tio T, Caletti G. Endosonography in Gastroenterology. World Congresses of Gastroenterology, Los Angeles, USA, Am J Gastroenterol (Suppl.), 1994.
- Gilja OH, Smievoll AI, Thune N, Matre K, Hausken T, Odegaard S, Berstad A. In vivo comparison of 3D ultrasonography and Magnetic Resonance Imaging in volume estimation of human

kidneys. *Ultrasound Med. & Biol.* 1995;21:25-32.

- Berstad A, Hausken T, Gilja OH, Thune N, Matre K, Odegaard S. Volume measurements of the antrum by 3D ultrasonography and flow measurements through the pylorus by duplex technique. *Dig Dis Sci*, 1995, 39(12):97-100.
- Gilja OH, Hausken T, Odegaard S, Berstad A. Monitoring post-prandial size of the gastric fundus with ultrasonography. *J Ultrasound Med*, 1995;14:81-9.
- Gilja OH, Hausken T, Odegaard S, Berstad A. Three- Dimensional ultrasonography of the gastric antrum in patients with functional dyspepsia. *Motility* 1998;412,15-17
- Berstad A, Hausken T, Gilja OH, Hveem K, Nesje L, Odegaard S. Ultrasonography of the stomach. *Scand J Gastroenterol.* 1996;31, (Suppl.220), 75-82.
- Menzel J, Domschke W, Brambs HJ, Frank N, Hatfield A, Nattermann C, Odegaard S, Seifert H, Tamada K, Tio TL, Foerster E. Minisonden - Sonographie im oberen Gastrointestinaltrakt - State of the art 1995 und Perspektiven. *Ultraschall in Med.* 17, 1996, 143-148.
- Caletti G, Deviere J, Fockens P, Lees WR, Mortensen MB, Odegaard S, Rösch T, Souquet JC, Vilman P. Guidelines of the European Society of Gastrointestinal endoscopy (E.S.G.E.). Endoscopic Ultrasonography. Technique and upper gastrointestinal tract. *Endoscopy* 1996;28:474-479.
- Menzel J, Domschke W, Brambs HJ, Frank N, Hatfield A, Nattermann C, Odegaard S, Seifert H, Tamada K, Tio TL, Foerster EC. Miniprobe Ultrasonography in the upper gastrointestinal tract: State of the art 1995, and prospects. *Endoscopy* 1996; 28: 508-513.
- Gilja OH, Hausken T, Odegaard S, Berstad A. Three-dimensional ultrasonography of the gastric antrum in patients with functional dyspepsia. *Scand J Gastroenterol* 1996;31:847-855.
- Molin SO, Jirås A, Hall-Angerås M, Falk A, Martens D, Gilja OH, Nesje LB, Martens D, Odegaard S. Virtual reality in surgical practice. In vitro and In vivo Evaluations. Medicine meets virtual reality: global healthcare grid. In: *Studies in health technology and informatics*, Vol.39, 1997, 246-253. H Sieburg, S Weghorst, K Morgan (Eds), IOS.
- Berstad A., Hausken T, Gilja OH, Nesland Aa, Odegaard S. Imaging studies in dyspepsia. *Eur J Surg* 1998; Suppl 582:42-49.
- Hausken T, Søndena K, Svebak S, Gilja OH, Olafsson S, Odegaard S, Søreide O, Berstad A. Common pathogenetic mechanisms in symptomatic, uncomplicated gallstone disease and functional dyspepsia. *Dig Dis Sci*, 1997, 42: 2505-2512.
- Odegaard S, Nesje LB, Gilja OH, Hausken T, Molin SO, Martens D. Diseases of the

gastrointestinal tract examined with 3D-endoscopic ultrasonography. In: Bismuth H et al,» Proceedings, 8th World Congress of the International Gastro-Surgical Club, Strasbourg», pp. 827-831, Monduzzi Editore, Bologna 1998.

- Odegaard S, Nesje LB, Ohm I, Kimmey MB. Endosonography in gastroenterological diseases. *Acta Radiologica* 1999;40: 119-134.
- Odegaard S, Nesje LB, Hausken T, Thierley M, Gilja OH, Takvam JA, Molin SO. Intraluminale Hochfrequente Sonographie in der Diagnostik von gastrointestinalen Krankheiten. *Ultraschall in Med* 2000;21: 47-58
- Hausken T, Gilja OH, Odegaard S, Berstad A. Flow across the human pylorus soon after ingestion of food, studied with duplex sonography. *Scand J Gastroenterol* 1998;33: 484-490.
- Gilja OH, Hausken T, Olafsson S, Matre K, Odegaard S. In vitro evaluation of three-dimensional ultrasonography based on magnetic scanhead tracking. *Ultrasound in Med & Biol* 1998;24.1161-1167
- Gilja OH, Hausken T, Odegaard S, Berstad A. Gastric emptying measured by ultrasonography. *World J Gastroenterol* 1999; 5:93-94
- Gilja OH, Hausken T, Berstad A, Odegaard S. Measurement of organ volume by ultrasonography. *Proc Inst Mech Eng* 1999; 213: 247-259.
- Folvik G, Bjerke-Larssen T, Odegaard S, Hausken T, Gilja OH, Berstad A. Hydrosonography of the small intestine: comparison with radiologic barium study. *Scand J Gastroenterol* 1999;34:1247-1252
- Odegaard S, Nesje LB, Molin SO, Gilja OH, Hausken T. Three-dimensional intraluminal sonography in the evaluation of gastrointestinal diseases. *Abdominal Imaging* 1999, 24. 449-451.
- Odegaard S. High resolution endoluminal sonography in gastroenterology. *Eur J Ultrasound* 1999;10:85-91.
- Odegaard S. (ed.). Endosonography in Gastroenterology, *Eur J Ultrasound, Special Issue (Editor)* 1999;10: 85-196.
- Molin SO, Nesje LB, Gilja OH, Hausken T, Martens D, Odegaard S. 3D-endosonography in gastroenterology: methodology and clinical applications. *Eur J Ultrasound* 1999;10: 171-177
- Nesje LB, Svanes K, Laerum OD, Odegaard S. Comparison of a linear miniature ultrasound probe and a radial-scanning echoendoscope in TN staging of esophageal cancer. *Scand J Gastroenterol* 2000;35:997-1002

- Odegaard S., Nesje LB, Kimmey MK. Endoscopic ultrasound miniprobos for gastrointestinal cancer staging. In: Bhutani MS, Tandon RK. (eds.) *Advances in Gastrointestinal Endoscopy*. JayPee Brothers Medical Publishers, New Delhi 2000.
- Bergamaschi R, Yavuz Y, Marvik R. Laparoscopic bowel resection: a comparison of three ultrasonically activated devices. *JSLs*. 2003 Jan-Mar;7(1):19-22.
- Bergamaschi R, Marvik R. Laparoscopic intracorporeal bowel resection with ultrasound versus electrosurgical dissection. *JSLs*. 2001 Jan-Mar;5(1):17-20.