

EFSUMB Course Book, 2nd Edition

Editor: Christoph F. Dietrich

Ultrasound in vascular diseases

**Colin Deane¹, Sergio Castellani², Boris Brkljačić³, Laurence Needleman⁴,
Christoph F. Dietrich⁵**

¹Vascular Laboratory, Department of Medical Engineering and Physics, King's College, London, UK.

²Department of Medical and Surgical Critical Care A.O.-U. Careggi, Associate Professor in Cardiovascular Diseases, Chair of Angiology, University of Florence, Florence, Italy.

³Department of Diagnostic and Interventional Radiology, University Hospital "Dubrava", professor of radiology, Medical School, University of Zagreb, Zagreb, Croatia.

⁴Department of Radiology, Sidney Kimmel Medical College, Thomas Jefferson University, Philadelphia, Pennsylvania, USA.

⁵Department Allgemeine Innere Medizin, Kliniken Beau Site, Salem und Permanence, Hirslanden, Berne, Switzerland

Corresponding author:

Colin Deane PhD

Vascular Laboratory,

King's College Hospital, London, United Kingdom SE5 9RS

E-mail: colin.deane@kcl.ac.uk

Introduction

Ultrasound is used extensively in the investigation of vascular disease; it provides B-mode imaging of anatomy and morphology with Doppler measurement of haemodynamics. Ultrasound's versatility, portability, safety and its ability to examine real-time changes makes it suitable to a range of applications from vascular physiology studies to rapid diagnosis of acute events in emergency settings.

Effective vascular ultrasound practice requires an understanding of the interactions of Doppler ultrasound and blood flow so that the operator can understand the colour and spectral display in terms of the underlying haemodynamics. This chapter begins with an overview of the Doppler ultrasound display of blood flow to help with the understanding of ultrasound's capabilities and occasional limitations, and as a reference for later clinical sections. A brief overview of flow through stenoses, fistulas and other arterial features is also given. The section concludes with Doppler assessment of venous flow.

Doppler displays: velocity

Spectral Doppler and colour flow imaging are derived from the measurement of movement. As blood flows through the ultrasound beam, the presence and direction of flow and the velocity component relative to the direction of the beam is detected and displayed [Figure 1]. In colour flow, this is displayed as a real-time map of movement in an area on the image; the information within the colour flow image is rarely used to provide quantitative information although each colour pixel does represent a velocity vector. In spectral Doppler the range of velocities along the beam at a specific sample volume is displayed graphically as a frequency spectrum [Figure 2], commonly called the Doppler sonogram.

Figure 1 Colour flow and spectral Doppler image of flow in a brachial artery. Flow is from screen left to right towards the transducer. The colour flow shows red as flow towards the colour flow beams which are vertically down the image. There is a slight velocity component towards the beam as the vessel becomes more superficial. Flow is therefore shown as red. The size of the spectral Doppler sample is the sample size shown by the two parallel lines on the dotted spectral Doppler line. The spectral

Doppler beam is angled to the left to obtain a beam/flow angle of 56° determined by the angle correction line parallel to the vessel wall inside the sample volume

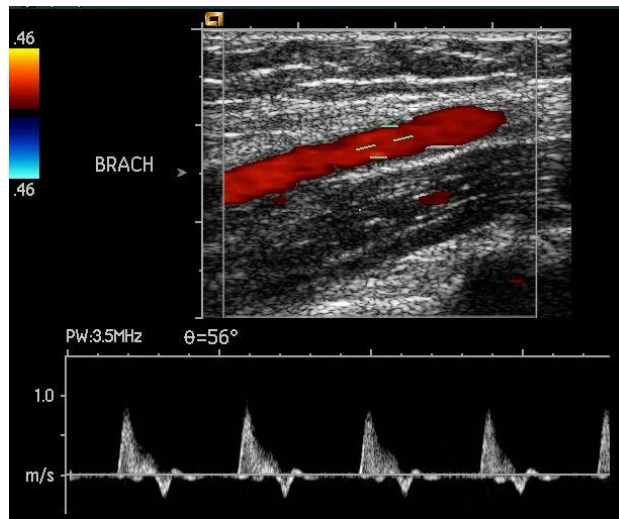
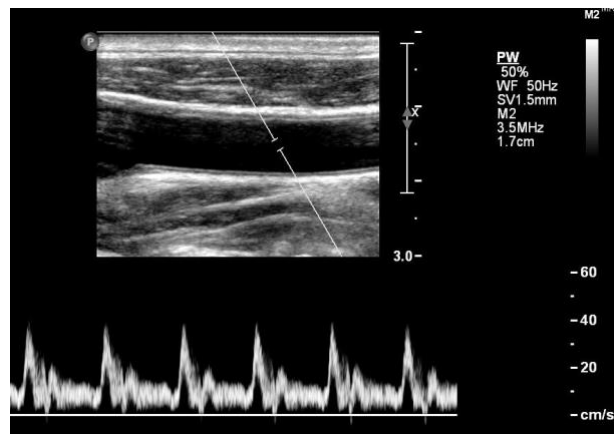
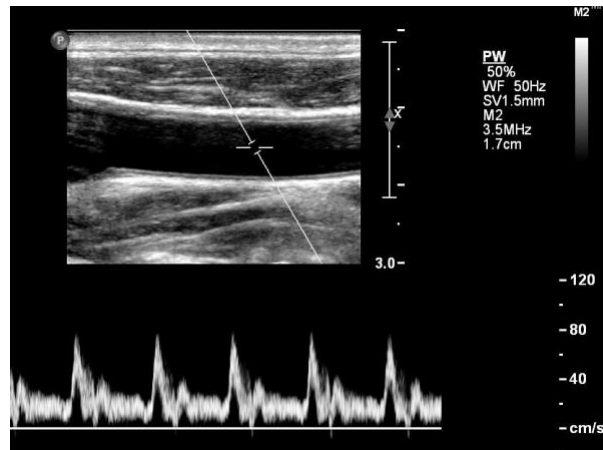


Figure 2 Sonogram from centre of a common carotid artery. The sample volume is placed in the centre of the vessel (a) and shows a time-changing range of velocity components. Not until an angle correction is made (b) does the velocity scale represent true velocities.

a



b



Strictly this is not a display of velocities until an angle correction between the beam and flow direction is made (until then the machine assumes a Doppler angle of 0). The Doppler sonogram is displayed at high temporal resolution and allows display of flow velocities, flow waveforms over time and, to a limited extent, an appreciation of the flow profile throughout the sample volume. Uniquely in imaging techniques, Doppler ultrasound provides an audio output of the sonogram. The pitch, dynamic changes and timbre are indications of the velocity, pulsatility and flow profile of the flow. These are difficult to describe in writing but are integral to the diagnosis for experienced practitioners.

Flow and velocity

The flow in a vessel (Q) is the product of mean velocity (V_{mean}) and cross-sectional area (A):

$$Q = V_{\text{mean}} \times A$$

Because Doppler is measurement of velocity, this has profound implications for Doppler ultrasound imaging. These include:

- If flow is low and the cross-sectional area large, then the resulting low velocities may be difficult to detect. This occurs in the major leg veins, for example when examining leg veins with the patient in standing, the veins are distended and resting flow is low. The low velocities may not be sufficient to register on the colour flow or Doppler image [Figure 3]. In this case, augmentation of flow may be required.

- As arteries subdivide into smaller branches, the total cross-sectional area increases and velocity decreases. For example, one renal artery, diameter approximately 5–6mm, typically divides into 5 segmental branches, then into interlobar, arcuate, interlobular and afferent arterioles that lead to around 1 million afferent arterioles, this all occurs within a distance of around 10cm. The increase in total area leads to low velocities in the arterioles that are below the level that Doppler ultrasound can image, because low velocities are removed by filters necessary to remove signals from tissue (particularly wall) motion [Figure 4]. Doppler ultrasound is restricted to conduit arteries and veins; for the imaging of very small vessels, contrast agents and alternative ultrasound techniques will be required.

Figure 3 A femoral vein confluence deep to the femoral artery. At this scale setting, flow in the artery is displayed but the venous flow velocities are too low to register in the image (note the open valve cusps indicating flow from R to L)

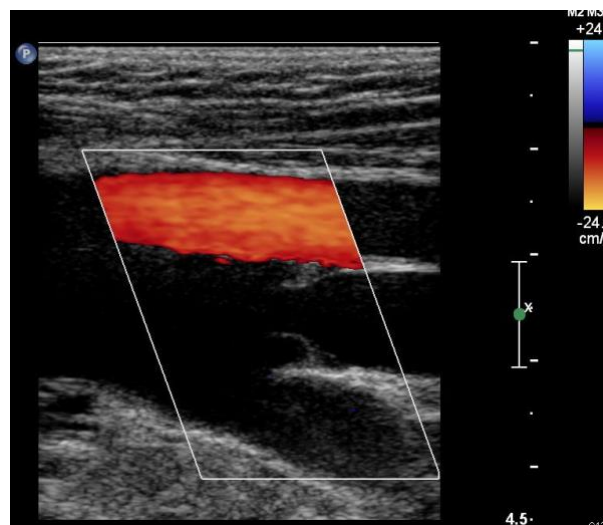
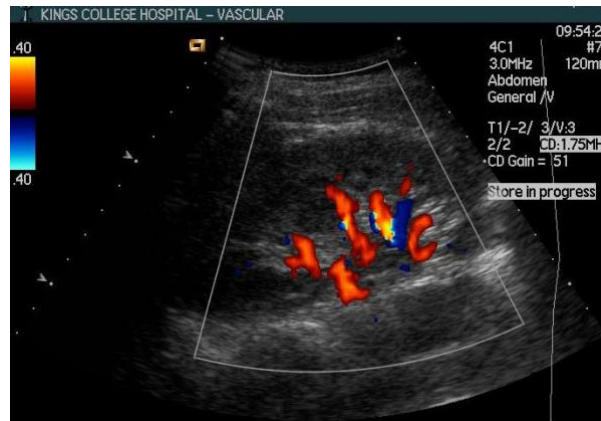
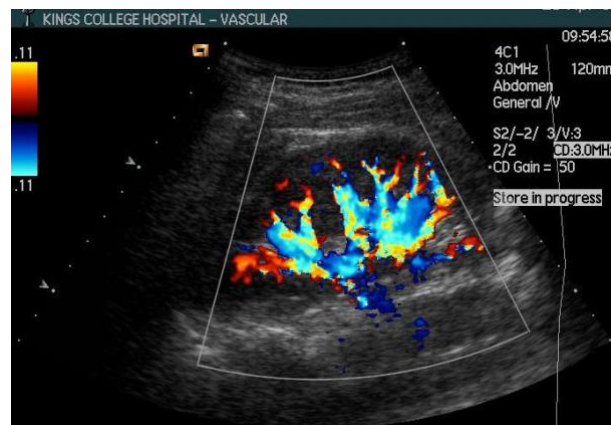


Figure 4 Colour flow in a kidney. At a medium colour scale setting (40) (L), flow in interlobar arteries is displayed. With the colour scale reduced (11), flow is seen further towards the renal capsule (R) but interlobular arteries and veins are still not imaged clearly.

a

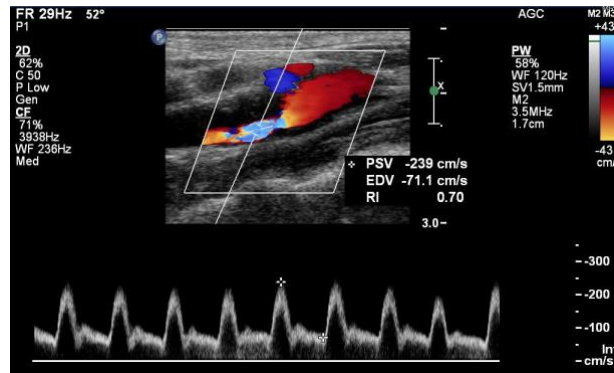


b



If an artery or vein is compressed or narrowed, velocities through it increases. This is observed in the jugular vein when light pressure causes the lumen to be squashed, which increases velocities through the vein. It is also extremely useful in the imaging and measurement of arterial stenoses (see later). The reduction in area at the site of stenosis leads to a corresponding increase in mean velocity and an increase in peak systolic velocity (PSV). The measurement of changes in PSV have proved to be invaluable in a range of vascular applications including, for example, carotid artery stenosis [Figure 5], peripheral artery disease and renal artery stenosis.

Figure 5 PSV measurement in a carotid stenosis. The colour Doppler lumen is narrowed and the elevated peak velocity of 239 cm/s indicates the presence and severity (approx 70%) of an ICA stenosis.



Peak velocities in healthy major arteries, *e.g.* carotid, femoral, renal and aorta are dependent on cardiac output, arterial impedance and other factors, but are typically in the range 50–120 cm/s and are higher in younger individuals and decrease with age. Peak velocities in the normal superior mesenteric artery and celiac axis can be higher, especially following a meal. Velocities exceeding 200 cm/s are usually indicative of narrowing. Velocities in severe disease can rise up to 600 cm/s, but there is insufficient pressure energy to drive velocities much higher than this. Venous velocities are generally lower, which is a result of the combination of lower pressures, more consistent flow throughout the cardiac cycle and larger vessels.

Doppler velocity measurement is subject to more errors than measurements made from B-mode (see ultrasound theory chapter). These possible errors include:

- Beam/flow angle errors (θ) that are worse with increasing angle, angles greater than 60° should not be used for absolute velocity measurement, angles of up to 70° can be used for more approximate measurements and, possibly, velocity ratios.
- Difficulty in determining direction of flow, especially in stenoses.
- Out-of-plane errors in velocity jet (the velocity component in the elevation plane).
- Intrinsic spectral broadening and variations within the image.

These restrict the accuracy of measurements of velocities. In practice, errors of at least 10% are not uncommon.

The application of absolute measurements to categorize stenosis is also subject to error from the range of normal values across the patient population due to physiological variation. This may be compensated for, to some degree, by using ratios, for example peak velocities of the internal and common carotid arteries and the renal artery and aorta peak velocity ratio.

Flow waveforms

The action of the heart causes pulsatile flow in large arteries. The flow waveform describes the time-changing nature of flow and is easily measured by Doppler ultrasound. The shape of the waveform is dependent on upstream, local and distal factors but at specific sites may be predominantly dependent on one factor, for example distal changes in resistance in the uterine artery in pregnancy. Analysis of flow waveform shape can be very useful at specific sites, for example as an indication of the level of disease in peripheral arterial disease [Figure 6] or as evidence of increased renovascular resistance [Figure 7].

Figure 6 Diagrammatic representation showing a normal flow waveform at the level of the external iliac artery and a severely damped (tardus parvus) waveform in the popliteal artery indicating a proximal occlusion.

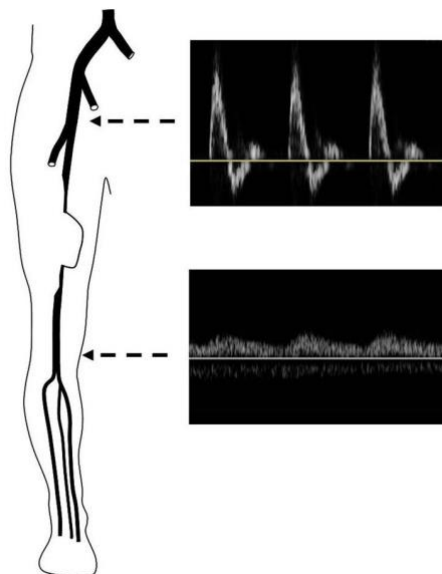
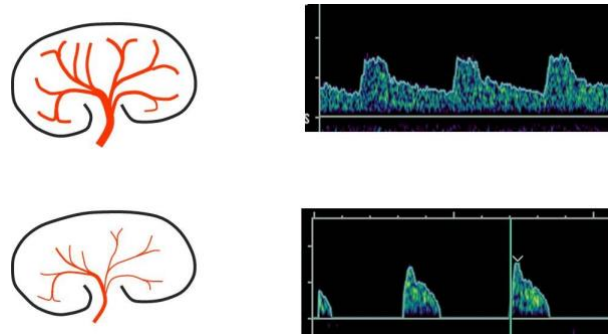


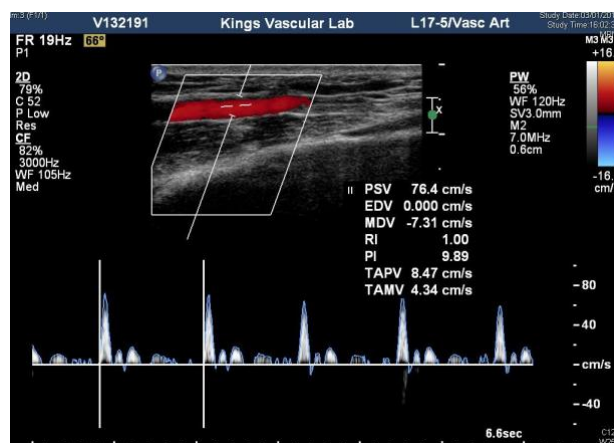
Figure 7 Normal (top) flow waveform from an interlobar artery in a kidney and the waveform (lower) in a case with severely elevated renovascular resistance.



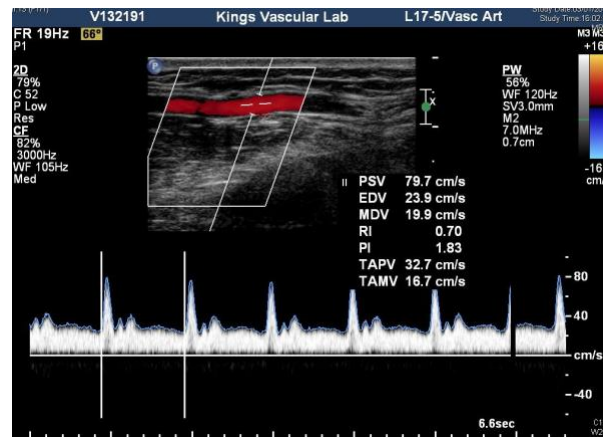
Arteries leading to a specific vascular bed have a characteristic flow waveform shape that are altered as a result of normal physiological [Figure 8] or abnormal pathological change.

Figure 8 Flow waveforms in a radial artery at room temperature (a) and with the hand immersed in warm water (b). Note the large increase in diastolic flow when the arterioles in the hand are vasodilated. Despite the fourfold increase in mean velocity, peak velocity is little changed.

a



b



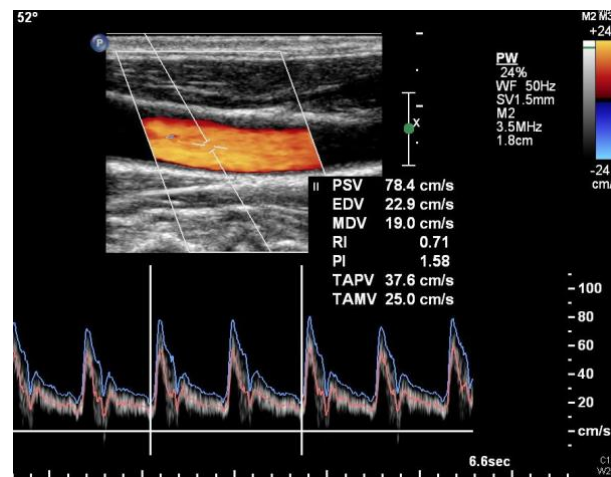
Gross changes in flow waveforms can be identified by eye but several descriptive measurements and indices have been used to provide numerical values for specific components of the waveforms. The most common of these are pulsatility index and resistive index, which are defined in Table 1 [Figure 9]. These are based on the outline shape of the waveform, the maximum frequency/envelope, and are, at best, fairly crude measures of flow waveform shape. Pulsatility index was first described as a means to measure the effects of proximal stenosis in peripheral arterial disease although it is now applied to changes in the uterine arteries and umbilical arteries as a measure of distal changes in resistance. These indices can be used to apply numerical values to the flow waveform to categorise gross changes in flow. They have the advantage that they are non-dimensional, and so are not affected by errors in measuring absolute velocities. Other descriptive measurements of the flow waveform shape include the acceleration and acceleration time of the systolic upstroke, and noting of a feature, for example of a post-systolic “notch” in the waveform.

Table 1 Pulsatility and resistance Index.

Index	Definition
Resistive index	$\frac{\text{Peak systolic velocity} - \text{end diastolic velocity}}{\text{Peak systolic velocity}}$

Pulsatility Index	<u>Peak systolic velocity - minimum diastolic velocity</u>
	Time averaged maximum velocity

Figure 9 Flow waveform indices. The pulsatility index and resistance index (PI, RI) are based on measurements from the outline of the flow waveform (blue line). The time averaged mean of the blue line is described as TAPV (time averaged peak) in this scanner. The red line shows the intensity-weighted mean velocity, the time averaged mean is described as TAMV.



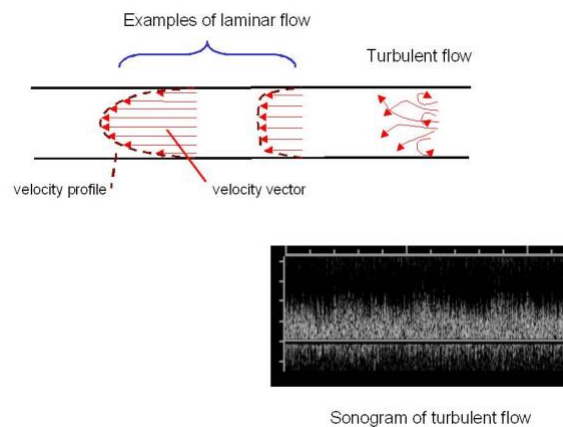
Flow profiles in spectral Doppler sonogram

The velocity distribution across the vessel and over the course of the cardiac cycle influences the flow waveform shape (the edges of the waveform). Velocities vary across a vessel at any time. Flow is slowest next to the vessel wall and is usually highest in the centre of the vessel. The range and distribution of velocity is described as the flow profile.

In normal conditions, flow in vessels is described as laminar: blood moves as a series of adjacent laminae that slide over each other. The flow profile may be blunt or may approach, or be, parabolic in shape. Blunt profiles have few to no slow velocities while parabolic have distributed velocities from high to low. Sonogram depiction of the flow profile is also dependent on how much of the vessel width is insonated by the sample volume (in small sample sizes only a small part of the vessel will be sampled, in larger volumes sampling the entire vessel may be possible).

Sudden accelerations in flow tend to produce a blunt profile. In turbulent flow, flow no longer moves in laminae but in irregular unpredictable directions including motion across the vessel. Turbulent flow results in a greater energy loss along the artery. Examples of laminar and turbulent flow are shown diagrammatically in Figure 10. Furthermore flow profile may not be symmetrical and can vary in different parts of a vessel. Curvature, bifurcations and confluences all produce secondary fluid flow, which may extend along an artery or vein. The asymmetry may vary throughout the cardiac cycle.

Figure 10 Flow profiles. The two flow profiles to the left show laminar flow of the type seen in figures 2, 5, 6, 7, 8 and 9. The flow to the right shows random, multidirectional flow, reflected in the sonogram.



The influence of flow profiles has consequences for Doppler ultrasound practice, including:

- The relation of peak velocity to mean velocity is dependent on flow profile. Perhaps the most significance is in the analysis of peak velocity changes through stenoses (see later). The ratio of peak velocities through a stenosis is dependent on the changing profile through the stenosis. Although mean velocity is directly proportional to the change in area, the change to peak velocity is less predictable.
- If mean velocity is to be measured in a vessel, then the Doppler sample volume should insonate all velocities equally. This is difficult to do in large vessels because the 2D image may omit the full width of the vessel in the elevation plane. However, the sample volume

displayed should encompass the entire width of the vessel in the imaged plane (see volume flow later).

Measurement of volume flow

Conventional Doppler volume flow measurements require multiplication of mean velocity and vessel area (or the area derived from diameter if the vessel is circular in cross-section).

As described by:

Volume blood flow = cross-sectional area of a vessel x mean velocity in the vessel

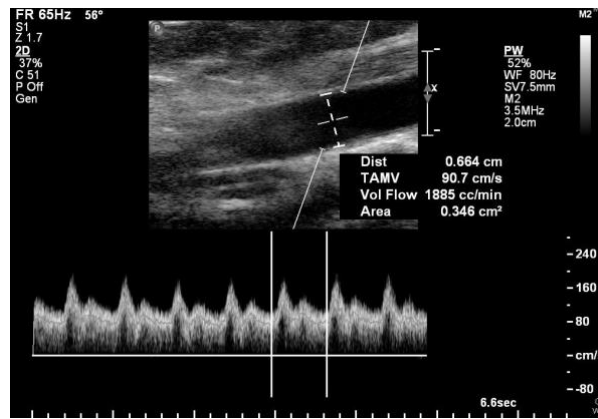
Possible errors in mean velocity measurement can occur:

- if the vessel flow is not sampled uniformly across its area,
- if a high wall filter is used (low velocities will be removed and the mean artificially raised),
- if adjacent vessels are included in the sample volume and
- if there are errors in beam/flow angle correction.

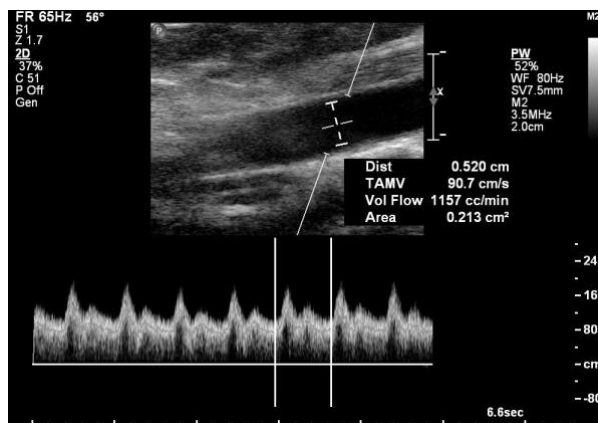
Errors in diameter can arise from the limited spatial resolution, errors in placing the cursors and errors if the true diameter is not imaged. For example, an error of 0.5mm in measuring a vessel of diameter 3mm leads to errors of over 30%. In combination with velocity measurement errors, this means large volume flow errors are possible [Figure 11].

Figure 11 Errors in volume flow. Values of volume flow showing the difference between diameter measurements of 6.6 and 5.2 mm. The 27% error in diameter leads to a 60% error in area with consequent differences in measured flow.

a



b



If volume flow measurements are being attempted, it is prudent to be aware of possible errors and to conduct tests to ensure results are reproducible. With care, ultrasound measurements of volume flow may be used in clinical studies to examine changes to flow in individuals and across a population. In clinical practice the one application in which ultrasound measurement of volume flow is routinely used is in the examination of haemodialysis fistula and graft accesses. Here the superficial position and relatively large diameters of the vessels and high flows through them make accurate measurement of vessel area and mean velocity feasible. Even so, errors of around 10–20% in volume flow measurement are possible. Despite this, ultrasound-derived volume flow is useful as an indication of access health.

Summary of Doppler measurement techniques

Flow waveform shape

Advantages:

- Does not require beam/vessel angle correction.
- Is reproducible across different ultrasound systems.
- Provides qualitative information on the circulation and changes in the circulation.
- Large database of results for with proven diagnostic capabilities.

Disadvantages

- Does not provide quantified flow.
- Indices most useful for measurement of arterial flow, less well proven for venous applications

Blood flow velocities

Advantages

- A measure of quantity, increases in velocities in a vessel implies an increase in flow.
- Can be measured reliably if beam/vessel angle correction is made
- Very useful to quantify stenoses.

Disadvantages

- Beam/vessel angle correction must be correct.
- Mean velocity measurements are subject to instrumentation errors.

Volume flow measurements

Advantages

- Quantified volume flow

Disadvantages

- Requires measurement of vessel area/diameter, only possible in comparatively large vessels

- Requires measurement of mean velocity in the spectrum. Difficult to get accurate results; very large errors are possible and likely.

Flow through specific features in the arterial circulation: Doppler appearances

Stenoses

The detection of and quantification of the severity of stenoses is of the utmost importance in vascular applications of ultrasound. Flow and pressure changes through significant stenoses lead to:

- Reduced pressure at the site of stenoses that, if the pressure is not recovered, leads to low pressure distally (for example this is important in renovascular hypertension).
- Reduced flow to the affected vascular bed (claudication, rest pain and mesenteric ischaemia).
- Conditions in which emboli may occur (carotid artery disease leading to embolic stroke).

Pressure loss through a stenosis and the consequent restriction to flow are related, and can be described as haemodynamic consequences in which the effects become more severe as the severity of the stenosis increases. The energy to accelerate the blood through the stenosis comes from a reduction in the blood pressure. If there is no energy loss, this change in energy is given by a modification of Bernoulli's theorem:

$$P + \frac{1}{2} \rho V^2 = \text{constant}$$

Attempts have been made to correlate the peak velocity in a stenosis jet to the resulting pressure loss in peripheral arteries with mixed success. Perhaps the most successful application is in the analysis of renal artery stenosis in which intraluminal pressure measurements have been shown to be well-correlated with the measured PSV.

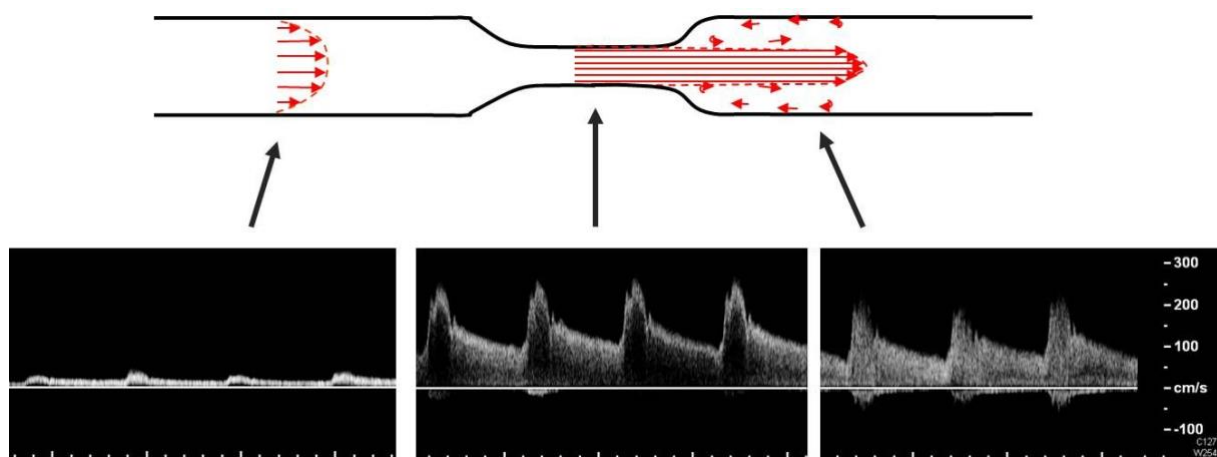
The embolic consequences of stenosis are more difficult to predict. Studies of carotid stenoses have shown that there is a general increased embolic activity with increasing level

of stenosis but the effects in an individual are unpredictable and are dependent on other factors including plaque composition and surface and blood properties.

The effects of a stenosis can be measured by Doppler ultrasound either directly by examining velocity changes at the stenosis site or indirectly by measuring flow waveform changes downstream. By far the most reliable technique, if it is possible, is to examine the changes at the site of the stenosis.

The changes in flow velocities occurring through a stenosis are shown diagrammatically in Figure 12.

Figure 12 Flow through a stenosis. Flow waveforms through a carotid stenosis. These waveforms are shown on the same scale and illustrate the large (6-fold) velocity increase from pre-stenosis to in-stenosis flow with turbulence evident as the jet slows down in the post-stenotic region.

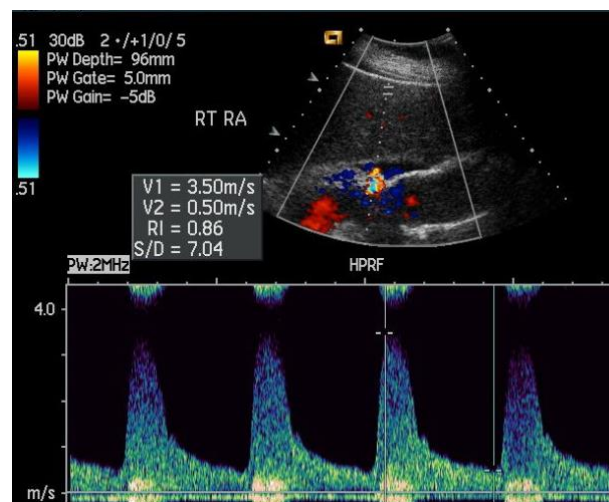


In clinical practice a stenosis may be identified by the presence of a stenotic jet in which velocities are increased and in which there is little spectral broadening due to the plug-like flow profile. Distally, there is an area of disturbed flow of turbulence as the jet dissipates into the post-stenotic lumen. Because of the changes in flow profile, minor stenoses (up to 40%) may not demonstrate significant PSV increases. Analysis is further complicated by the unpredictability of the stenoses geometry, a 50% diameter stenosis can lead to a reduction in cross-sectional area from 25–75% depending on its shape.

In theory, velocity measurement through a stenosis should provide an accurate measure of the degree of narrowing of the vessel. Continuity of flow means that the decrease in lumen size is accompanied by a corresponding rise in mean velocity in the vessel. Unfortunately, mean velocity is difficult to measure accurately with Doppler techniques. Additionally, stenoses often occur near or at bifurcations so that comparison of proximal velocity to velocity within the stenosis is limited by the multiple vascular beds that the proximal vessel supplies. PSV does not change in proportion to the mean velocity rise. The flow profile through the stenosis becomes plug-like so that a halving of area does not lead to twice the peak velocity (although mean velocity would increase by that much).

Criteria for velocity increases have been obtained empirically and have been shown to be reliable in, for example, disease of the internal carotid artery [Figure 5]. It may be that the only evidence obtained in some abdominal sites is a high velocity; in such cases, there is no need to try to image the pre- or post-stenotic flow [Figure 13].

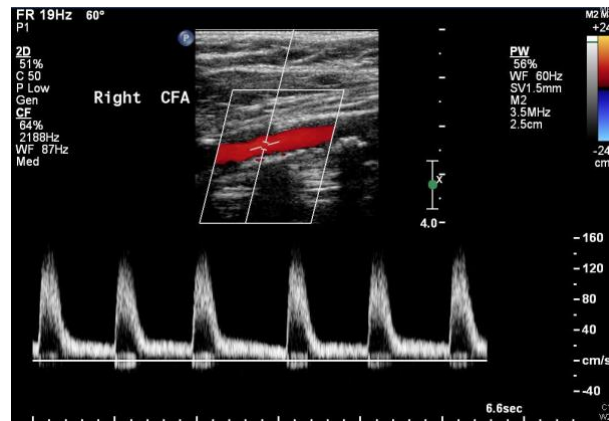Figure 13 Renal artery stenosis. Despite no angle correction, a velocity of 3.5 m/s is displayed at the renal artery origin, indicating a severe stenosis.



If the narrowing is severe enough, the pressure loss through the stenosis causes damped flow distally [Figure 14]. The pressure drop can be exacerbated by increasing blood velocity through the stenosis. This is particularly important in aorto-iliac disease in which moderate

stenoses may cause no effect at rest but when the patient exercises can lead to pressure losses caused by increased velocities at the stenosis.

Figure 14 Damped flow downstream. Flow in a common femoral artery downstream of a tight iliac stenosis. When compared with a normal resting waveform (figure 19a), there is forward flow throughout diastole as well as systole.



Bifurcations

The flow at large bifurcations is often complicated by the presence of a time-varying region of flow separation and strong secondary flows. Velocities are usually highest at the dividing wall with flow separation probable at the opposite wall. The extent and duration of the region of separation is dependent on several factors, including the angle of bifurcation. These factors can make it difficult to measure velocity components accurately within the bifurcation region. The waveform becomes more ordered (due to the gradual damping of secondary flow) distally.

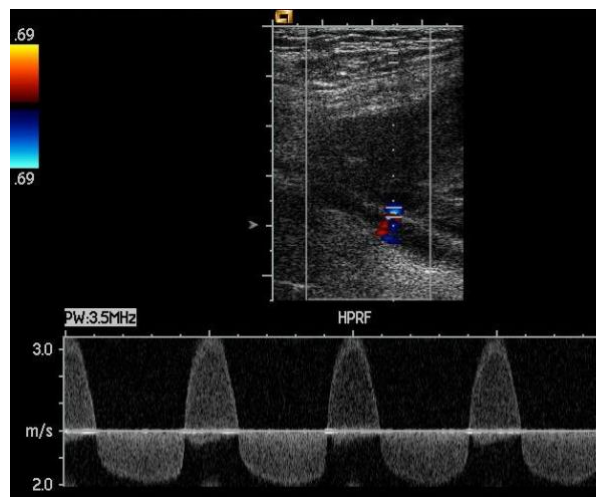
Curvature

Curvature can cause skewing of the velocity profiles from one side to the other. If severe enough to cause kinking, curves can give rise to narrowings. In severe cases, accurate interpretation of the colour image may be difficult and can produce errors in the measurement of flow velocity vectors.

Aneurysms and pseudoaneurysms

Flow in aneurysms is typified by large secondary flows due to the sudden increase in cross-sectional area and increase in local static pressure. Swirling, multidirectional flow is often seen in the colour image. The Doppler spectrum may show disordered flow depending on the position of the sample volume. Pseudoaneurysms also often show evidence of a swirling flow pattern, which may be cyclic. The artery feeding to the pseudoaneurysm demonstrates forward flow in systole and complete reversal of flow in diastole [Figure 15].

Figure 15 Flow in pseudoaneurysm. The flow in the tract to a pseudoaneurysm shows flow entering the sac in systole before being expelled in diastole.

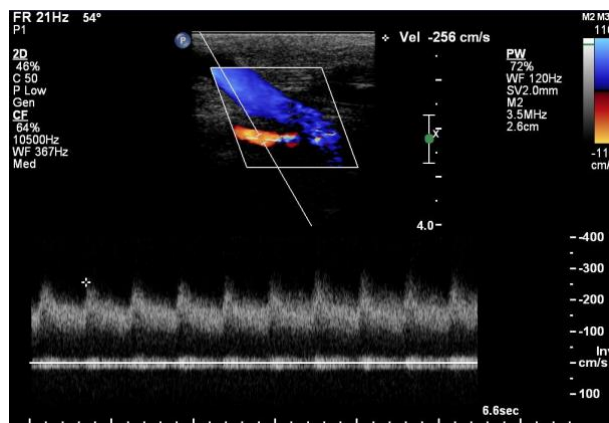


Arteriovenous fistulas

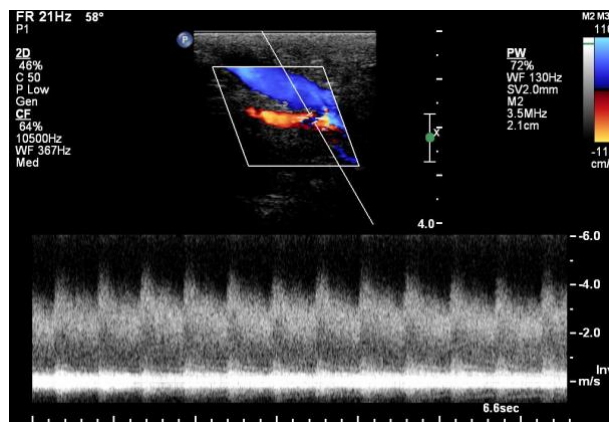
Whether created intentionally or not, arteriovenous fistulas present a path of low resistance between an artery and vein. Doppler findings usually show a high velocity low pulsatility flow waveform in the artery leading to the fistula [Figure 16] with disturbed flow at the artery-vein junction. Flow here is usually turbulent with a large pressure drop due to high velocity flow entering the vein. Further along the vein, flow becomes more orderly and may show arterial-like pulsations.

Figure 16 Flow in a fistula. Flow in the artery to the fistula (L) shows a high velocities throughout the cardiac cycle related to the large arteriovenous pressure gradient. Close to the fistula there is evidence of turbulence (centre) and multidirectional flow. The flow in the vein (R) shows evidence of the turbulence and also shows cycle increases in velocity from the arterial pulse ("arterialization of the vein")..

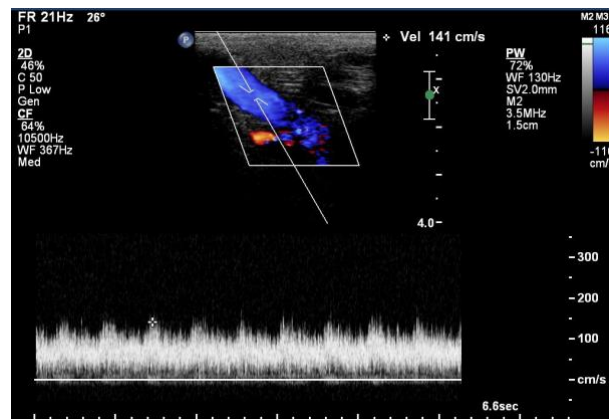
a



b



c



Venous flow

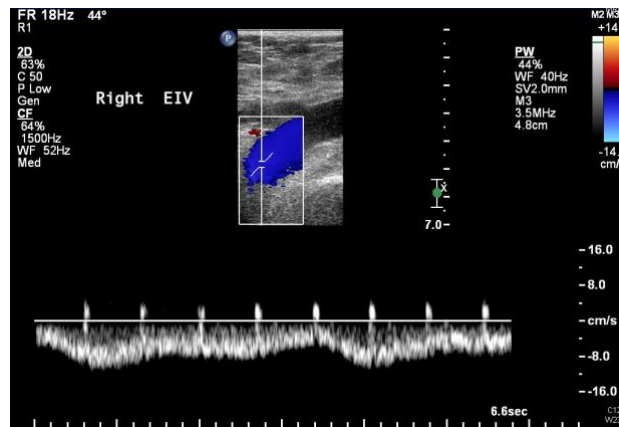
Compared with arterial flow, venous flow is characterised by lower velocities, pulsatility that depend on downstream pressure changes, and by low-pressure vessels that are often readily compressed. Because of the lower velocities, scanner settings for Doppler investigation of veins are different from those used for arterial flow. Typically a lower pulse repetition frequency and more persistence are used to enhance the venous signals. The amount of pulsatility varies considerably depending on the site being measured. Veins in the upper abdomen exhibit fluctuations caused by back-pressure changes from the right atrium. These may be further modulated by changes in intrathoracic pressure caused by breathing. Further away from the heart (in the iliac veins for instance) the breathing changes dominate. In the extremities (the tibial veins for example) there may be little natural variation in velocity. Changes can be induced by asking the patient to cough or by asking them to perform a Valsalva manoeuvre. Flow may augmented by squeezing a limb.

The presence of naturally occurring changes that occur in phase with breathing or the right heart is an indication that there is no major occlusion or thrombosis between the vena cava and the site of measurement. Bilateral differences (for example a right femoral vein with fluctuations, a left femoral vein with constant velocity) give cause for suspicion that one side has proximal thrombus or obstruction present [Figure 17].

Venous reflux in the legs is easily demonstrated by Doppler ultrasound. With the patient in standing, squeezing the patient's calf sends blood up towards the heart. If the venous valves are functioning adequately, a release of the calf causes a slight backflow (as blood descends under gravity), which is quickly checked by closure of the valves. In cases of incompetent valves, the blood flows back down the leg. In patients with high venous pressure, the velocity fluctuations caused by the action of the right heart are transmitted better through the veins, with less damping. The sudden changes in venous velocity may give the impression of arterial flow in cases where the anatomy is unclear. Careful study of the spectral display can usually clarify this.

Figure 17 Venous differences R to L. The right external iliac vein showed fluctuations from pressure changes due to breathing (left image). The absence of these fluctuations on the L were indicative of proximal thrombus (right image).

a



b

